



Master's Program in Clinical Laboratory Science

**Pathophysiology and Molecular Characterization of  
Cutaneous and Mucosal Melanoma**

**By**

Hanadi ALkhatib

**Advisors**

Dr. Mohammad Farraj

Dr. Tamer Essawi

This thesis was submitted in partial fulfillment of the requirements for the Master's degree in medical laboratory science from the Faculty of Graduate Studies at Birzeit University, Palestine

2017



# Pathophysiology and Molecular Characterization of Cutaneous and Mucosal Melanoma

By

Hanadi Al-Khatib

This thesis was successfully defended and approved on: 17 May 2017

## Committee Members

Tamer Essawi, PhD, Supervisor

Mohammad Farraj, PhD, Supervisor

Wail Hammoudeh, MD, Internal Examiner

Bilal Abu Fkhaida MD, External Examiner

## Signature









## **Dedication**

This dissertation is dedicated to my mom Ferial, my dad Ghalib, grandma Fatima, my sisters Hana'a, Sana'a and Amani, and brothers Sa'ed, Mohammad and Abdel-Rahman. I would also like to dedicate this work to my dear husband Dr. Nimer.

## **Acknowledgements**

I would like to express my appreciation to everyone who helped me throughout this work starting with Dr. Areej Khatib who helped me in choosing my topic and guided me throughout this work. Also I would like to thank my supervisors and teachers Dr. Mohammad Farraj and Dr. Tamer Essawi who provided me with help and support. Special thanks go to Mr. Israr Sabri who helped me in conducting my experiments and analyzing the results. Also I would like to thank Miss Dania Dejeni for her help.

HGK

# Table of Contents

<b><u>Chapter</u></b>		<b><u>Page</u></b>
1.	Introduction .....	5
1.1.	Cutaneous Melanoma .....	5
1.1.1.	Definition, Clinical Characteristics and Diagnosis .....	5
1.1.2.	CM Subtypes .....	7
1.1.3.	Causes and Risk Factors .....	12
2.	Mucosal Melanoma .....	13
2.2.1.	Definition, Clinical Characteristics and Diagnosis .....	13
2.2.1.	Causes and Risk Factors .....	15
2.2.3.	Mucosal Melanomas of The Respiratory Tract .....	16
2.2.4.	Mucosal Melanoma of Gastrointestinal Tract .....	17
2.2.5.	Mucosal Melanoma of Urogenital Tract .....	20
3.	Melanoma Staging and Treatment .....	21
4.	Melanoma Mutations .....	25
4.1.	NRAS Mutation .....	25
4.2.	BRAF Mutation .....	28
4.3.	C-KIT Mutation .....	30
5.	Materials and Methods .....	31
5.1.	Tumor Samples .....	31
5.2.	Cell Culture .....	31
5.3.	DNA Extraction .....	34
5.4.	Mutational Analysis .....	37
6.	Results .....	38
7.	Discussion .....	49
8.	References .....	56

# List of Figures

Figure 1	Superficial spreading melanoma “SSM” .....	10
Figure 2	Nodular Melanoma “NM” .....	10
Figure 3	Lentigo Maligna Melanoma “LMM” .....	11
Figure 4	Acral Lentiginous Melanoma “ALM” .....	11
Figure 5	NRAS Pathway .....	28
Figure 6	Melanoma cell culture .....	32
Figure 7	Melanoma cell culture .....	33
Figure 8	Monolayer of aggressive mucosal melanoma .....	33
Figure 9	Monolayer of aggressive mucosal melanoma .....	34
Figure 10	Agarose gel electrophoresis for BRAF, NRAS and CKIT controls .....	40
Figure 11	Agarose gel electrophoresis for CKIT 11, and 13 .....	40
Figure 12	Agarose gel electrophoresis for CKIT 11 and 13 and 17 .....	41
Figure 13	Agarose gel electrophoresis for BRAF .....	41
Figure 14	Agarose gel electrophoresis for BRAF .....	42
Figure 15	Agarose gel electrophoresis for NRAS .....	42
Figure 16	Sanger sequencing of BRAF reverse WT .....	43
Figure 17	Sanger sequencing of BRAF forward mutation .....	43
Figure 18	Sanger sequencing of NRAS forward WT .....	44
Figure 19	Sanger sequencing of NRAS reverse WT .....	44
Figure 20	Sanger sequencing of NRAS forward mutation .....	45
Figure 21	Sanger sequencing of KIT 11 forward WT .....	45
Figure 22	Sanger sequencing of KIT 11 forward WT .....	46
Figure 23	Sanger sequencing of KIT 11 forward mutation .....	46
Figure 24	Sanger sequencing of KIT 13 forward WT .....	47
Figure 25	Sanger sequencing of KIT 13 forward WT .....	47
Figure 26	Sanger sequencing of KIT 13 forward mutation .....	48
Figure 27	Sanger sequencing of KIT 17 forward WT .....	48

## List of Tables

Table 1	The mono therapy medical drugs and recommended worldwide .....	24
Table 2	High and low interferon alpha-2 recommended doses .....	25
Table 3	The primers used for each gene mutations .....	37
Table 4	Cell lines tested, DNA concentration and the type of mutations .....	39



## List of Abbreviations

CM	Cutaneous Melanoma
SSM	Superficial Spreading Melanoma
NM	Nodular Melanoma
LM	Lentigo Melanoma
LMM	Lentigo Maligna Melanoma
ALM	Acral Lentiginous Melanoma
MM	Mucosal Melanoma
RGP	Radial Growth Phase
VGP	Vertical Growth Phase
UV	Ultraviolet
GTP	Guanosine Triphosphate
GDP	Guanosine Diphosphate
MAP	Mitogen Activated Protein
Erk	Extracellular Signal-Regulated Kinase
ETS	Erythroblast Transformation Specific
PI3Ks	Type I Phosphatidylinositol-3-Kinases
RALGDS	RAL Guanine Nucleotide Dissociation Stimulators
PKC	Protein Kinase C
dNTPs	Nucleoside Triphosphate
PCR	Polymerase Chain Reaction
DMBM	Dulbecco's Modified Eagle Medium
FBS	Fetal Bovine Serum
RPM	Round Per Minute
WT	Wild Type

## **Abstract**

Cutaneous melanoma (CM) is an aggressive fatal skin malignancy arises in proliferating pigment producing melanocytes. Its characterized by ABCDE criteria, and diagnosed by applying this mnemonic rule, with other auxiliaries such as dermoscopy, distal dermoscopy and biopsy. This type of melanoma includes four different types, SSM, NM, LMM, and ALM. CM is caused mainly by direct UV exposure to the sun, tanning beds and other DNA mutations such as BRAF and NRAS.

Mucosal melanoma (MM) is more aggressive than CM, which results from melanocytes proliferation of mucosal membranes mainly in respiratory, gastrointestinal and urogenital tracts. Unlike CM, which is widespread in males, MM is more frequently encountered in females with a female to male ratio of 1.85-1.00.

This type of melanoma is poorly diagnosed at early stages of the disease because of its location in unexposed body sites and the absence of early symptoms. One of the risk factors implicated in sinonasal MM is formaldehyde exposure while

smoking can be involved in oral MM. C-kit is considered the most common mutation associated with MM.

Melanoma staging is determined based on tumor thickness, nodal involvement degree and tumor metastases, and it divided into five progressive stages. The treatment varies according to patient's status, which could be surgical removal, radiotherapy, chemotherapy, and mono-therapy.

Twenty-four melanoma cell lines, 13 CM, 8 MM, and 3 acral obtained from Palestinian patients with melanoma were used in this study. These cell lines were grown and maintained following established procedures in the tissue culture laboratory. DNA was extracted by the salting out method and used for subsequent amplification and sequencing. These procedures were used to detect mutations in the following oncogenes: BRAF exon 15, NRAS Q16 exon 3, and CKIT exons 11, 13, and 17.

The sequencing results detected mutations in BRAF 57.1%, NRAS 14.2%, KIT 29%, where KIT 11, 14.2%, KIT 13 14.2% and no mutations were detected in KIT 17.

## ملخص الرسالة

يعتبر سرطان الجلد السطحي من الامراض الخبيثة الفتاكة. ينشأ هذا المرض نتيجة لنمو الخلايا الصبغية. يمكن وصف هذه الخلايا بمقياس ABCDE وتشخيصها بالإضافة الى هذا المقياس باستخدام عوامل أخرى مساعدة مثل Dermoscopy, Distal dermoscopy and Biopsy. يوجد أربعة أنواع مختلفة من سرطان الجلد: SSM, NM, LMM, and ALM نتجت جميعها إثر التعرض للأشعة فوق البنفسجية المباشرة للشمس، الأشعة التي يتعرض لها الاشخاص لدبغ جلودهم وجعله مسمرًا. بغض النظر عن مصدر الأشعة فوق البنفسجية فالتعرض لها لفترات طويلة يتسبب بنشوء طفرات في الحمض النووي مثل NRAS و BRAF.

سرطان الجلد المخاطي هو أكثر عدوانية من سرطان الجلد السطحي، نتيجة انتشار الخلايا الصبغية في الأغشية المخاطية كالجهاز التنفسي، الجهاز الهضمي والمسالك البولية التناسلية. على عكس CM، الذي هو على نطاق واسع في الذكور، MM هو أكثر تواجدا في الإناث مع نسبة الإناث إلى الذكور من 1.85-1.00. هذا النوع من سرطان الجلد لا يتم تشخيصه الا في المراحل المتأخرة من المرض بسبب تواجده في مواقع الجسم غير المكشوفة وغياب الأعراض المبكرة. أحد عوامل الخطر المتورطة في سرطان الجلد المخاطي هو التعرض لمادة الفورمالديهايد، بالإضافة فان التدخين يمكن أن يلعب دور في حدوث هذا المرض. ويعتبر CKIT الطفرة الأكثر شيوعا المرتبطة بهذا النوع من سرطان الجلد.

يتم تحديد الورم الميلانيني بالاعتماد على سمك الورم، ومدى انتشاره في العقد الليمفاوية من جهة وأعضاء الجسم من جهة أخرى. يمكن التعرف على خمس مراحل متتالية عند تشخيص هذا المرض. يختلف العلاج وفقا لحالة المريض، والتي يمكن أن تكون إزالة الورم جراحيا، العلاج الإشعاعي، العلاج الكيميائي، والعلاج الأحادي.

استخدمت في هذه الدراسة أربعة وعشرون عينة من خلايا سرطان الجلد، 13 خلايا سرطان جلدي سطحي، 8 سرطان جلدي مخاطي، و3 سرطان جلدي من الأطراف. تم الحصول عليها من المرضى الفلسطينيين الذين يعانون من سرطان الجلد. تم زراعة هذه الخلايا والحفاظ عليها باتباع الإجراءات المعمول بها في مختبر زراعة الأنسجة. تم استخراج الحمض النووي بواسطة طريقة التلميح خارجا وتستخدم لتضخيم لاحق والتسلسل. وقد استخدمت هذه الإجراءات للكشف عن الطفرات في الجينات المسرطنة التالية: BRAF اكسون 15، NRAS اكسون 3، و CKIT اكسون 11 و 13 و 17.

كشفت نتائج التسلسل عن طفرات في BRAF 57.1%، NRAS 14.2%، CKIT 29%، حيث CKIT 11، 14.2%، CKIT 13، 14.2% ولم يتم الكشف عن أي طفرات في CKIT 17.

# **1. Introduction**

## **1.1. Cutaneous Melanoma**

### **1.1.1. Definition, Clinical Characteristics and Diagnosis**

CM is long been considered a highly heterogeneous disease<sup>1</sup>. It is one of the major aggressive types of skin tumors, abnormally arising by proliferation of melanocytes in the epidermis<sup>2</sup>, and it is potentially recognized as fatal among overall skin cancer types<sup>3</sup>. CM is responsible for about 75 % of all deaths from skin cancers even though it forms only around 3-5 %<sup>4</sup>. Tumor metastasis to distant organs is accountable for the majority of melanoma related death. Only 14% of metastatic melanoma patients survive for 5 years and the reason for that referred to the diagnosis at late stages, whereas the large majorities, which account for more than 85% of patients diagnosed with melanoma, cured due to diagnosis at early stages of tumor progression<sup>5</sup>.

The early detection and clinical guide of melanoma diagnosis follows the ABCDE criteria. This criteria stands for asymmetry of the lesion, borders irregularity, color variation which is different from one region to another; dissimilar shades of tan, brown, black; sometimes red, white, or blue within the same lesion. Diameter,

which is usually, more than 6 mm<sup>6</sup> and finally evolving lesion which helps in the evaluation especially if it arises from mole, which will be different in size, shape and color from the other normal ones in the body<sup>7</sup>. Hence, ABCDE criteria is considered the reference clinical characteristics of melanoma skin lesions; however, the most experienced clinicians have problems and difficulties diagnosing pigmented lesions properly, and clinical accuracy of diagnosis infrequently outrun 60%. Even though, CM may not be simply diagnose by applying ABCDE mnemonic rule<sup>8</sup>. Therefore, pathological examination must be performing for the diagnosis<sup>9</sup>.

Early melanoma diagnosis may do using dermoscopy, and digital dermoscopy. The method that has been considered a useful tool to increase the accuracy in melanoma diagnosis by 10-27%<sup>10</sup> and gives diagnosis in early stages even in the absence of specific criteria for malignancy<sup>11</sup>. To complete the diagnosis and obtain accurate results, biopsy must take since it is an essential and initial step in the management of malignant melanoma and any suspicious lesion must be biopsied<sup>12</sup>. Excision biopsy is the recommended technique for suspected melanoma tumor as it enables diagnosis, staging, treatment, and determines future examination, while incision biopsy is suitable only for large lesions in some sensitive regions like the face and in the regions of a recent change within a giant congenital naevus<sup>13</sup>.

Biopsies, such as punch and shave are not recommended, because they do not permit total histological staging<sup>14</sup>.

### **1.1.2. CM Subtypes**

Four main histopathological types of melanoma has been recognized, the superficial spreading melanoma “SSM”, nodular melanoma “NM”, lentigo maligna melanoma “LMM”, and acral lentiginous melanoma “ALM”<sup>15</sup>.

#### **I. Superficial spreading melanoma “SSM”**

SSM considered the most common type of CM since it accounts for about 65% of all melanoma cases diagnosed<sup>16</sup>. Initially, it starts as slow radial growth phase (RGP) before becoming invasive, with a clinical characteristic of asymptomatic brown or black patch that could be asymmetric with irregular borders, or variations in color<sup>17</sup>.



## **II. Nodular Melanoma “NM”**

NM is the second most common subtype of CM that accounts for 15-30% and around 40% to 50% of other melanomas thicker than 2 mm<sup>18</sup>. Unlike other melanoma subtypes, NM has a vertical growth phase (VGP) of melanocytes which grow gradually as a round nodule that ulcerate, crust and bleed in advanced stages<sup>19</sup>. Hence, it has been rapidly invasive, aggressive, ulcerated, with more mitotic activity compared to SSM type<sup>20</sup>. NM differs from other subtypes of melanomas since they originate from different stem cell types, this is, dermal stem cells whereas the other subtypes arise from epidermal stem cells<sup>21</sup>. NM is 80% symmetrical with regular border and single color, which mostly could be red, or pink that regularly spread throughout the lesion. Therefore, ABCDE mnemonic rule is unhelpful, and EFG rule is another suggested aide that has been introduced for the identification of clinical features of NM that stands for elevated, firm and progressively growing lesion for more than a month<sup>22</sup>.

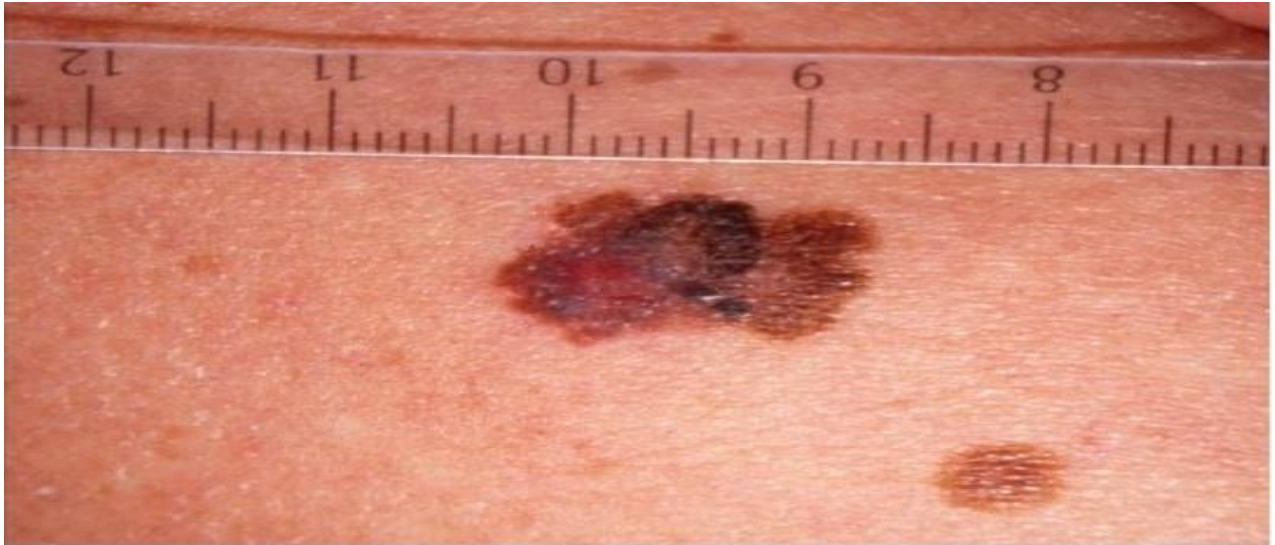## **III. Lentigo Maligna Melanoma “LMM”**

This type of pigmented lesions develops with time from lentigo maligna “LM” to become invasive LMM after it increases in size<sup>23</sup>. Mainly it occurs because of sun exposure that leads to skin damage particularly in the head and neck regions<sup>24</sup>. It

accounts for 4-15% of CM and occurs less commonly than SSM and NM<sup>25</sup>. LMM lesions are usually flat and slightly raised in certain areas, irregular borders, hyperpigmented with multiple colored varies from brown to black<sup>26</sup>.

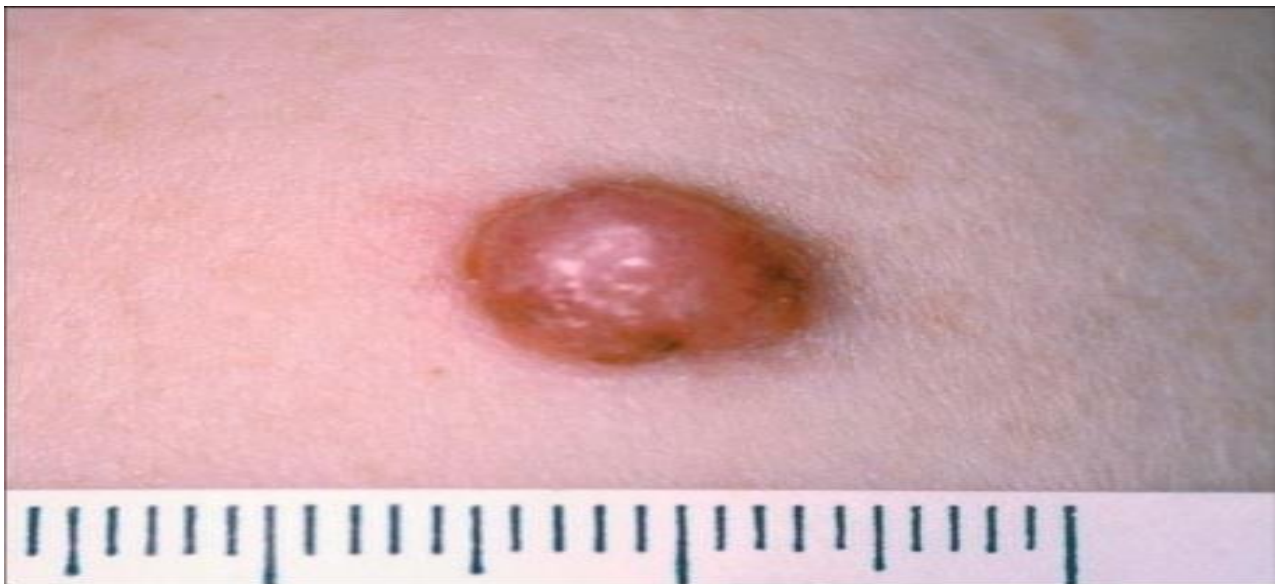#### **IV. Acral Lentiginous Melanoma “ALM”**

ALM is a very aggressive tumor<sup>27</sup>. It occurs on volar surfaces of hands and feet, subungual sites, and fingers or toes<sup>28</sup>. This type of melanoma has a slow RGP and central plaque like thickening. Also deeply pigmented tumor cells, obviously thickened papillary dermis, and diffuse reticular infiltration, all are considered the most common characteristic of ALM, lesions are remarkably large and in most cases they are thick and ulcerated<sup>29</sup>, However, it is described to have a poorer prognosis than melanomas of other histotypes<sup>30</sup>. ALM accounts for 5% of all melanomas<sup>31</sup>. However, population database shows that, it is linked with a worse prognosis than any other CM <sup>32</sup>. The molecular hallmarks of ALM are CCND1 amplifications or somatic mutations in c-KIT<sup>33</sup>. KIT mutations are common in ALM and it accounts 23%<sup>34</sup>.



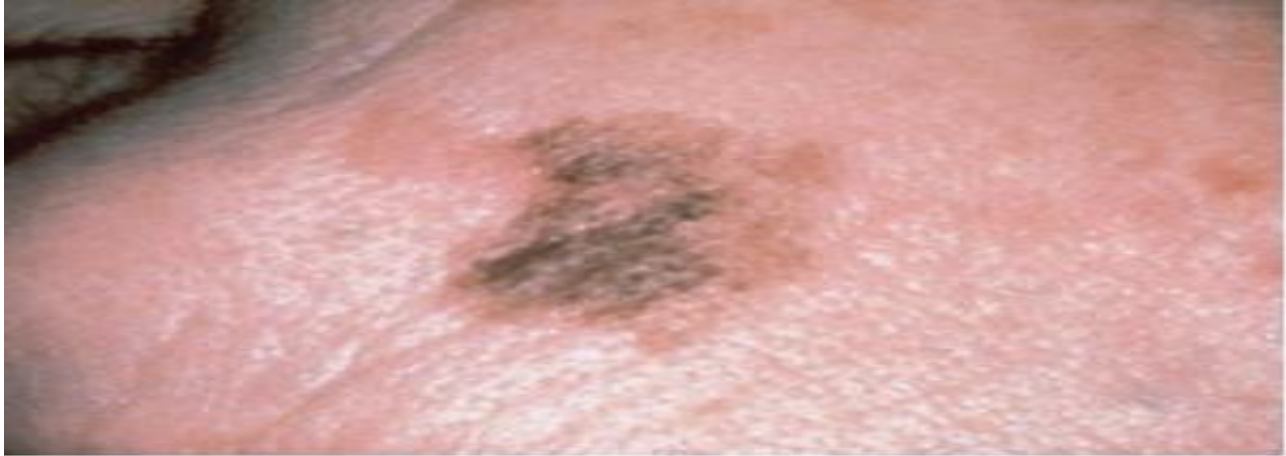**Superficial Spreading Melanoma**  
Noto, Giuseppe. "On the clinical significance of cutaneous melanoma's precursors." *Indian dermatology online journal* 3.2 (2012): 83.

Figure 1: Superficial spreading melanoma “SSM”.



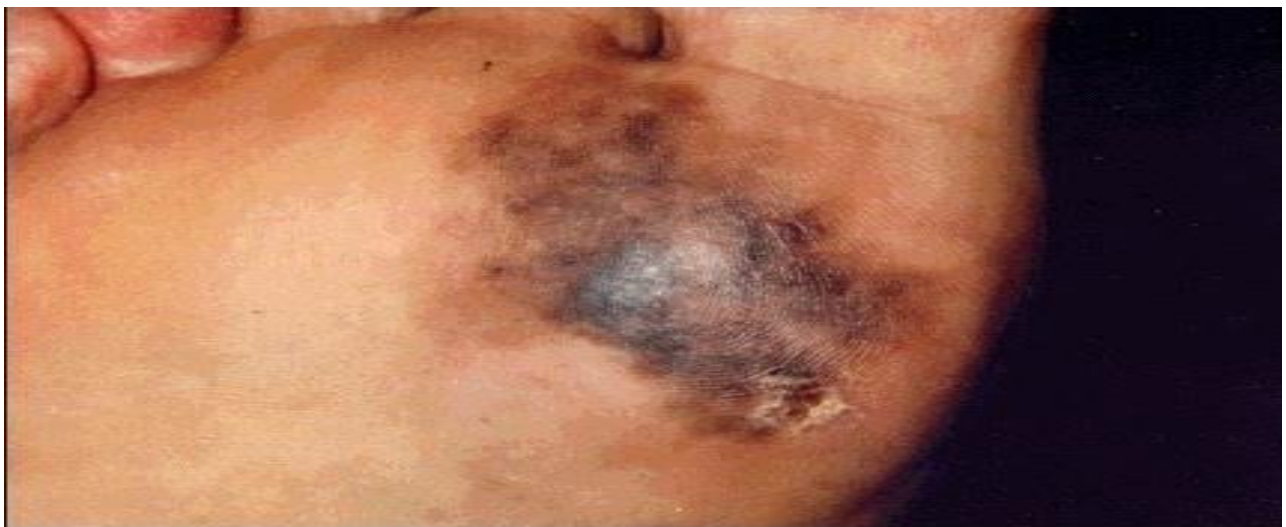**Nodular Melanoma**  
Kelly, John W., et al. "Nodular melanoma." *No longer as simple as ABC.* *Aust Fam Phys* 32 (2003): 706-709.

Figure 2: Nodular Melanoma “NM”.



**Lentigo Maligna Melanoma**  
Jerant, Anthony F., et al. "Early detection and treatment of skin cancer." *American family physician* 62.2 (2000): 357-386.

Figure 3: Lentigo Maligna Melanoma "LMM"



**Acral Lentiginous Melanoma**  
Swetter, Susan M., Alan C. Geller, and John M. Kirkwood. "Melanoma in the older person." *ONCOLOGY-WILLISTON PARK THEN HUNTINGTON THE MELVILLE NEW YORK*- 18.9 (2004): 1187-1196.

Figure 4: Aral Lentiginous Melanoma "ALM"

### 1.1.3. Causes and Risk Factors

There are several environmental or genetic factors are involved in causing melanoma. The most important environmental factor associated with CM is exposure to ultraviolet (UV) radiation from the sun. The disease progression is associated directly to the UV wavelength, which ranges from 100 - 400 nm<sup>35</sup>. Those are largely categorizing into UV A light “315-400” nm, which reaches the earth’s surface almost unabsorbed. UV B “280-315” nm which is incompletely absorbed by the atmospheric ozone layer, and UV C “100-280” nm which is entirely absorbed by the earth’s atmosphere<sup>36</sup>.The most common primary DNA mutations are induced by UV B irradiation occurring at DNA sites having pyrimidine, giving primary photo products cyclobutane pyrimidine dimers and 6-4 pyrimidine-pyrimidone, which cause DNA mutations if not removed by cellular repair activity<sup>37</sup>.While the mutations occurring after exposure to UV A irradiation lead to purine photo- adduct formation, so Guanine bases are altered and converted to 8-hydroxydeoxyguanosine (8-OHdG) which acts as a miscoding lesion resulting in G to T transversions<sup>38</sup>.

Other non-solar UV source that plays an important role in causing melanoma is tanning beds, and there is strong association between the UV dose response tanning bed used and the risk of melanoma. The association is stronger for patient’s exposure at a younger age<sup>39</sup>.

At the molecular and genetic levels, SSM and NM have a much advanced frequency of BRAF and NRAS mutations than other melanoma subtypes, whereas ALM and MM of the genital region have much higher probability to the presence of KIT mutations<sup>40</sup>.

## **2. Mucosal Melanoma**

### **2.2.1. Definition, Clinical Characteristics and Diagnosis**

Primary mucosal melanoma (MM) arises from melanocytes found in the mucosal membranes lining respiratory, gastrointestinal and urogenital tracts. MM is rare, but it is more aggressive and has less favorable prognosis compared to other subtypes of melanoma. Since, this condition is rare, knowledge and information about its pathogenesis and risk factors are insufficient. Furthermore, protocols for staging and treatment of this type of melanoma<sup>41</sup> are not well recognized.

MM may occur in any mucosal surface in the body, but the most familiar and regular areas where it occurs are the head, neck, the anorectal mucosa, and the vulvo vaginal mucosa. MM unlike CM, which is more widespread in males, is

more frequently diagnosed in females with a ratio 1.85-1.0. vulvo vaginal melanoma frequency in females has been considered the most common subtype, whereas head and neck are the most common areas that affect men<sup>42</sup>. MM represents only about 1.4% of all melanomas<sup>43</sup>. There are various manifestations of MM with different symptoms, e.g., in the respiratory track the most common symptoms observed are unilateral nasal obstruction, mass lesion, and epistaxis<sup>44</sup>. While the symptoms found in the gastrointestinal track, include abdominal pain, weight loss, upper gastrointestinal bleeding and anemia<sup>45</sup>. The most common presenting symptoms in MM of urogenital tract are vaginal bleeding and discharge, presence of mass lesion, and less common pain<sup>46</sup>.

In general, the diagnosis of MM is poorly recognized at early stages of the disease because of the hidden sites and the absence of early symptoms. Confirmation mainly obtained at late stage when several lesions become ulcerated. Therefore, this condition is not easy assessed. The nonappearance of junctional change in an ulcerated lesion does not prevent the possibility that the lesion is a primary melanoma<sup>47</sup>. Immunohistochemical staining positive for protein S-100, HMB-45, Melan-A, Mart-1 and tyrosinase support diagnosis of melanoma<sup>48</sup>.

### 2.2.2. Causes and Risk Factors

MM is different from CM where it occurs in areas that are not exposed to the sun. Therefore, the risk factors for the progression of this type of melanoma have not been recognized. One of the risk factors suggested for sinonasal MM is formaldehyde exposure. Therefore, exposure to formaldehyde considered a professional hazard among staff exposed to this substance<sup>49</sup>. For oral MM, cigarette smoking was proposed as risk factor, because it has been confirmed that oral pigmented lesions are more widespread among smokers<sup>50</sup>.

At the molecular and genetics level, there is a strong association between C-KIT gene mutation and MM. In addition, other gene mutations that affect the PTEN and P53 tumor suppresser genes may be involved. Other mutations that lead to this type of melanoma include mutation in GNAQ<sup>Q209</sup> gene in exon 5 and GNA11<sup>R183</sup> gene mutation. The details about these mutations exist in the mutations section.



### **2.2.3. Mucosal melanomas of the respiratory tract**

MM in the respiratory tract found mainly in the nasal cavity and paranasal sinuses, whereas it is very uncommon in the mucosa of larynx or tracheobronchial tree. On the other hand, lungs considered the most common site for metastatic MM, and other types of melanoma like ocular and CM<sup>51</sup>. Although MM of the respiratory tract is most common in nasal cavity, paranasal sinuses and nasopharynx, it considered a rare tumor and accounts for about 4% of all sinonasal malignancies<sup>52</sup>, whereas nasal cavity is central site accounting for about 80% of melanomas in sinonasal tract<sup>53</sup>. Elderly are more susceptible for sinonasal tract MM with a mean age of 64 years<sup>54</sup>.

There are several symptoms have been noticed in MM of respiratory tract, including unilateral nasal obstruction, mass lesion, epistaxis, also pain and facial distortion may occur with proptosis and diplopia which are rare in advanced stages. Those patients occasionally diagnosed due to the occult location of melanoma. The ones who started with epistaxis typically refer to physician earlier than the ones

with obstructive symptoms. Therefore, macroscopically, most of tumors appear as ulcerated polypoid brown to black pigmented mass<sup>55</sup>.

Despite the possible difficulties encountered with surgical removal, which is limited by surrounding structures, it remains the main treatment of choice because even radiotherapy has not shown improvement in overall patient's survival<sup>56</sup>.

#### **2.2.4. Mucosal melanoma of the gastrointestinal tract**

The most common sites where MM occurs in gastrointestinal tract are anorectal, with a ratio of 31.4% in the anal canal, 22.2% in the rectum, oropharyngeal area with 32.8% ratio, esophagus 5.9%, stomach 2.7%, small bowel 2.3%, gallbladder 1.4%, and large bowel 0.9%, which is very uncommon site of origin<sup>57</sup>. Approximately 50% of gastrointestinal MM patients are older than 70 years, and 14% are younger than 50 years. The colon, stomach and small intestine considered the most common areas of metastatic MM in gastrointestinal tract<sup>58</sup>.

Oral melanomas arise initially from melanocytes normally exist in oral mucosa<sup>59</sup>. It has been verified that the concentration of melanocytes in the lower lip increase with age especially in men, hence the mean age of this type of melanoma is 59

years. Oral melanoma typically arise de novo, but it progresses from pre-existing melanocytic lesion in almost one third of patients<sup>60</sup>. It may occur in any place of the oral cavity, but hard palate and maxillary gingiva considered the most common affected areas, while other areas such as mandibular gingiva, labial and buccal mucosa, tongue, tonsils, uvula and parotid gland are rarely affected<sup>61</sup>. In this type of melanoma, the patient initially will be asymptomatic, presenting macular and flat lesion and sometimes it could be slightly elevated and irregular pigmented lesion. In later stages of the tumor prognosis, the lesion swells and becomes ulcerated, bleeds and cause pain with occasional tooth mobility sometimes<sup>62</sup>. Patients with oral melanoma show 25% regional lymph node metastases. In this case, surgery is considered the main treatment option, and can be accompanied with radiotherapy and chemotherapy. Despite all measures taken, prognosis remains poor<sup>63</sup>.

Mucosal melanoma of the esophagus is a very rare tumor that accounts for 10.2% of all esophageal malignances. It occurs typically in the middle and lower part of esophagus since the melanocytes are concentrated there. Their number increased in areas of hyperplastic epithelium and chronic esophagitis, while approximately 10% of cases are located in the upper third of esophagus<sup>64</sup>. On the other hand, the melanocytes in the stomach and intestinal epithelium have not been demonstrated.

Therefore, the origin of melanoma in these sites remains unknown. The same can be applied to the primary melanoma of the small intestine with possible explanation pointing melanoblasts the origin on the tumor, which migrate to the distal ileum through the omphalomesenteric canal. Another suggestion says; all melanomas in the small intestine arise by metastases from unidentified primary CM<sup>65</sup>.

MM which occurs in the ano-rectal area, is considered the most common one amongst primary melanomas of the gastrointestinal tract, and the third most common site after cutaneous and ocular melanomas<sup>66</sup>. Lesions may affect anal canal, rectum or both, but the most common ones are located within 6cm of the anal rim. Wide local excision is the initial treatment of choice in this case<sup>67</sup>. In contrast, the primary melanoma of the biliary tract is very uncommon and may arise in the gall bladder or bile duct. 9 cases of bile duct melanoma were reported in the literature, and 30 cases of melanoma in the gallbladder<sup>68</sup>. Melanomas on the biliary tract are metastatic widely, and tend to be found as multiple, smooth pigmented lesions, while the primary tumors are found as singular, polypoid lesion on gross examination<sup>69</sup>.

### **2.2.5. Mucosal melanoma of the urogenital tract**

MM may occur in any part of the urogenital tract including the vagina, uterine cervix, vulva, urethra and urinary bladder. This type of melanoma is more common in females than males, accounting for 18% of genital tract and 3% of urinary tract<sup>70</sup>. Amongst genital tract in females, the most common occurrence is in vulva which accounts for 76.7% and considered the most common tumor after squamous cell carcinoma in the vulva, followed by vaginal MM which accounts for 19.8%, whereas cervical melanoma has the least occurrence<sup>71</sup>.

Vulvar melanoma frequently occurs in old women, with an average age 68 years<sup>72</sup>. Clitoral zone, labia majora and minora and peri-urethral are the most common sites where urogenital MM may occur, whereas vaginal introitus is the least common<sup>73</sup>. There are major symptoms that are associated with this type of melanoma including bleeding, vulvar mass, pruritus and irritation, with discomfort and discharge<sup>74</sup>.

### 3. **Melanoma Staging and Treatment**

Melanoma staging is determined based on the TNM classification system, which take into account the tumor thickness, nodal involvement degree and tumor metastases<sup>75</sup>.

There are five stages of melanoma:

- Stage 0, known as in situ melanoma, it is confined to the epidermis only without spreading into deeper layers.
- Stage I, is also confined to the skin and do not spread, but thicker up to 1 mm. This stage divided into two parts:
  - Stage IA, the skin that covers melanoma is still intact.
  - Stage IB the skin covering melanoma is broken and ulcerated<sup>76</sup>.
- Stage II, the melanoma is thicker ranging from 1.01 – 4 mm. It is not spread to other parts of the body including lymph nodes. Ulceration may or may not be seen. Stage II is divided into three parts:
  - Stage IIA, the melanoma thickness ranges between 1-2 mm and ulcerated, or between 2-4 mm without ulceration.
  - Stage IIB is ulcerated with 2-4 mm thickness or un-ulcerated with thickness more than 4 mm.
  - Stage IIC is ulcerated with more than 4 mm thickness<sup>77</sup>.

- Stage III, melanoma has spread to one or more lymph nodes or near skin. It's divided into three stages:
  - Stage IIIA, is not ulcerated and extend into up to three lymph nodes which are not enlarged in close proximity to the primary tumor.
  - Stage IIIB, where the same spreading to 1-3 lymph nodes without enlargement has seen. In this stage the lesion is ulcerated, but could also be un-ulcerated with enlargement of the lymph nodes or un-ulcerated and spread to tiny areas of skin or lymphatic channels, but nearby lymph nodes do not have melanocytes.
  - Stage IIIC, where melanocytes have seen in lymph nodes or lymph channels, and in small areas of skin surrounding those areas. It may be seen as ulcerated and spread to 1-3 enlarged lymph nodes. It may spread to more than 4 mm with or without ulceration.
  
- Stage IV, the melanoma has spread to distinct lymph nodes far from the primary site of melanoma and reaches several internal organs elsewhere in the body. It may be seen in parts of the skin far from the primary site. Lungs, liver and brain have all considered the most common sites of metastatic<sup>78</sup>.

There are different options for melanoma treatment. The first is by the surgical removal of the primary lesion, ensuring total removal of the lesion and the surrounding areas that may contain melanoma cells. This radical treatment prevents possible recurrence. Definitive surgical treatment typically should occur no later, than three to four weeks after biopsy result<sup>79</sup>. Surgical excision takes into consideration a safety margin of additional 1 cm in tumors up to 2 mm thick, and 2 cm in thicker tumors<sup>80</sup>. Radiotherapy is another treatment of choice that is inferior to surgery. Radiotherapy is an alternative treatment option for inoperable tumors<sup>81</sup>. In macroscopic tumors the radiation recommended dose is 70 Gy, five sessions per week with two individual doses of 2 Gy individually. In microscopic tumors, the radiation recommended does is 60 Gy with individual doses of 2 Gy. Three dimensional radiation planning should be performed to guarantee the radiation homogenous distribution in the affected sites and to spare the adjacent normal tissues<sup>82</sup>. In case of inoperable recurring tumors, inoperable local metastases, and stage IV metastases melanoma the recommended treatments are chemotherapy and chemo-immunotherapy<sup>83</sup>.

As for advanced stages of melanoma, systemic mono-therapy with several substances that have high clinical effectiveness is available. The mechanism here is



that mono-chemo therapy has the ability to shrink tumor cells and decrease tumor symptoms. The mono-therapy medical drugs used and recommended worldwide are listed in the table below<sup>84</sup>.

<b>Drug</b>	<b>Dosage</b>	<b>Responsiveness rate</b>
Dacarbazine	250 mg/m <sup>2</sup> i.v., days 1–5 every 3–4 weeks	12.1–17.6%
	Or 800–1200 mg/m <sup>2</sup> i.v., day 1 every 3-4 weeks	5.3–23%
Temolozomide	150–200 mg/m <sup>2</sup> oral, days 1–5 every 4 weeks	13.5–21%
Fotemustine	100 mg/m <sup>2</sup> i.v. days 1, 8, and 15, followed by 5 week interval, to be repeated every 3 weeks	7.4–24.2%
Vindesine	3 mg/m <sup>2</sup> i.v. every 14 days	12–26%
Interferon alpha	9m–18m IU/m <sup>2</sup> s.c. 3×/week continuous administration	13–25%
Interleukin-2	600 000 IU/kg as 15 minute short infusion i.v. every 8 hours on days 1–5 (maximum 14 individual doses), repeat cycle day 14	16–21.6%

Table 1: The mono therapy medical drugs and recommended worldwide.

Due to the high ability of melanoma to become metastatic, and the limited therapeutic choices for inoperable tumor, medicine lately follows the adjuvant therapeutic approaches. The most adjuvant therapy used for ulcerating primary tumors is interferon, thus decreasing patient’s mortality. Depending on the patient

status low dose or high dose treatment with interferon alpha is applied<sup>85</sup>. High and low interferon alpha-2 recommended doses are listed in Table 2.

<b>Scheme</b>	<b>Dosage</b>
Low dose interferon alpha-2	3m IU s.c. 3×/week over 18–24 months
High-dose interferon alpha-2b Initial treatment	20m IU/m <sup>2</sup> i.v., days 1–5 over 4 weeks
Maintenance treatment	10m IU/m <sup>2</sup> s.c., 3×/week over 11 months

Table 2 : High and low interferon alpha-2 recommended doses.

## **4. Melanoma Mutations**

### **4.1. NRAS mutation**

Ras proteins play an important role in molecular switching for transmission of the regulatory signals since they are involved with the intrinsic GTPase activity and cycle between inactive GDP-bound form and active GTP-bound form<sup>86</sup>. Huge numbers of reports indicate that RAS gene mutation screening in melanoma tumors have been observed since they appeared in literature, and there are three closely related proto-oncogenes, encoding the H-Ras, K-Ras and N-Ras proteins, respectively are habitually found in their mutated oncogenic forms in human tumors<sup>87</sup>.

Around 20% of human tumors have activating RAS point mutations. These mutations mainly found in codons 12, 13 or 61, and these investigations consistently point to NRAS codon 61 as being the most common RAS alteration in primary sporadic melanomas, with reported frequencies fluctuating from 4 to 50%. Where the most frequently observed NRAS codon 61 mutations are the Q61R (CAA/CGA) and Q61K (CAA/AAA) changes leading to substitutions from glutamine to arginine or to lysine respectively<sup>88</sup>. Activating mutations in the KRAS and HRAS genes were in contrast, recorded at very low incidences<sup>89</sup>. RAS gene affected by tumor specific mutations, since for example carcinomas of the pancreas; the colon and lung all have high occurrences of KRAS mutations<sup>90</sup>. While NRAS mutations, are common in myeloid leukemias and among CM<sup>91</sup>.

In the active form of GTP-bound, RAS stimulated three closely associated proteins, A-RAF, B-RAF, and C-RAF. Hence activated RAF will bind to the plasma membrane, phosphorylates and activates MAP-kinases Mek1 and Mek2, consequently the mitogen activated kinases Erk1 and Erk2 are phosphorylated and activated which leads at the end to ETS protein family phosphorylation. In addition to that, there are extra cytoplasmic proteins, capable to permit the nuclear

membrane, and activate the nuclear transcription factors Fos and Jun. The final consequence is the expression of cyclin D and other regulators in the cell cycle, leading to progression and transformation in it, with an additional functions which are regulated by the MAPK pathway, such as cells differentiation, senescence and apoptosis or survival<sup>92</sup>.

Another effector pathway which RAS acts; is its ability to interact with type I phosphatidylinositol-3-kinases (PI3Ks) leading to anti apoptotic effects. In addition to that it can regulate the actin cytoskeleton and other transcription factor pathways by helping of Rac and Rho family of proteins. Also it can affect the RAL proteins by RAL guanine nucleotide dissociation stimulators (RALGDS) and other associated proteins with additional effects for cell cycle regulation. Another RAS related activity done by phospholipase C linking RAS to Protein Kinase C (PKC) activation and calcium mobilization<sup>93</sup>.

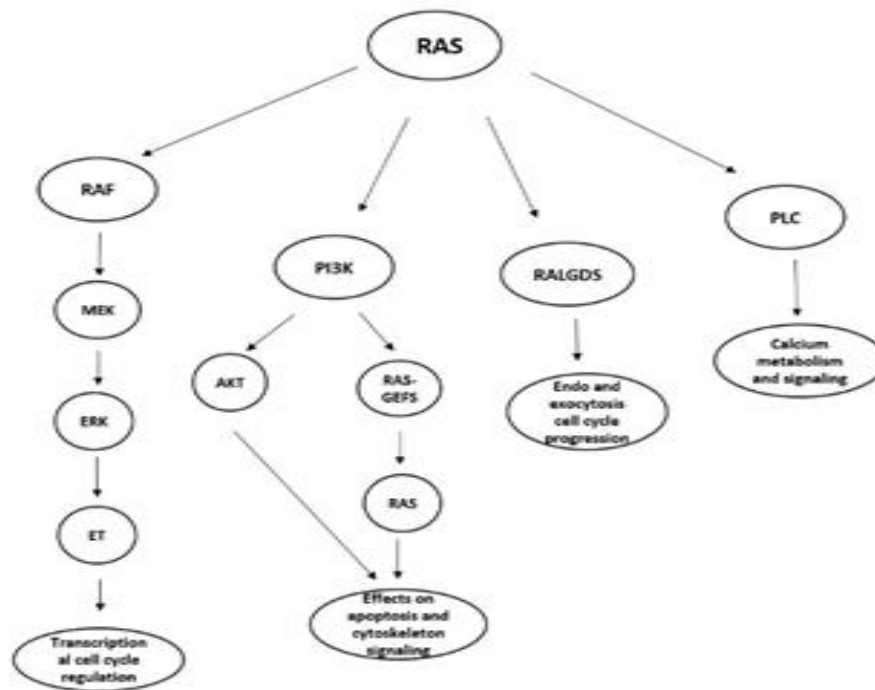


Figure 5: NRAS pathway

## 4.2. BRAF mutation

BRAF is a serine/threonine kinase encoded on chromosome 7q34<sup>94</sup>. It activates the MAPK, Erk, Erk cascade, interacting directly with MAPK and Erk 1. In addition, it plays a role as an anti-apoptotic, although the mechanism for this function is not clear<sup>95</sup>. The most common BRAF mutation detected in overall tumors including melanoma is codon 600 valine to glutamate (V600E) mutation<sup>96</sup>. Around 80% of

benign nevi carry this mutation<sup>97</sup>. BRAF V600 is sited in the activation segment of the kinase domain adjacent to T599 and S602, which are on phosphorylation outcome in kinase activity<sup>98</sup>. The V600E mutation may mimic the T599/S602 phosphorylation since V600E mutant BRAF has an advanced kinase activity than wild type BRAF<sup>99</sup>.

BRAF mutation incidences range from 20–80%. Among the BRAF mutations observed in melanoma, over 90 % are at codon 600, and amongst these, over 90% are a single nucleotide mutation as a result in substitution of glutamic acid for valine (BRAF V600E: nucleotide 1799 T>A; codon GTG> GAG). The second most common mutation is BRAF V600K, a result of lysine for valine substitution that represents 5-6 % (GTG> AAG). Followed by BRAF V600R mutation, as a result of substitution of valine (V) to an arginine (R)(GTG> AGG), an infrequent two-nucleotide variation of the predominant mutation, BRAF V600 'E2' (GTG> GAA), and BRAF V600D (GTG> GAT) mutation from valine (V) to an aspartic acid (D)<sup>100</sup>.

### 4.3. C.KIT mutation

At the molecular level, BRAF and NRAS mutations have been rarely found in MM<sup>101</sup>, whereas the gene encoding receptor tyrosine kinase KIT mutations and or increased in copy numbers have been seen in up to 40% of MM<sup>102</sup>. The thing that makes KIT is the most commonly altered oncogene recognized in MM so far. This opened the door for MM treatment option concerning the target therapy for this gene, which becomes more obvious after noticing the clinical response of KIT-mutated MM to tyrosine kinase inhibitors such as Imatinib, sorafenib and dasatinib<sup>103</sup>.

Several processes including proliferation, survival and apoptosis will be affected when mutation in c-kit gene occurs since it works as a tyrosine kinase receptor, which stimulates multiple downstream signaling cascades, such as MEK, RAF, ERK and PI3K, AKT pathways<sup>104</sup>. Hence, the transformed melanocytes express abnormalities in the c-kit, in the endothelin receptor type B, endothelin pathway, and in the Wnt/ $\beta$ -catenin pathway, in addition to that, it shows abnormality in cell-adhesion molecules<sup>105</sup>. In atypical melanocytes, increased c-kit protein expression is mainly associated with activating mutations suggesting a relevant function of the proto-oncogene KIT in the progress of oral mucosal melanoma<sup>106</sup>.

## **5. Materials and methods**

### **5.1. Tumor samples**

Twenty-four melanoma cell lines were obtained from Dr. Lotem's Laboratory in Hadassah medical center. These cell lines were established from Palestinian melanoma patients. Ten cell lines represented cutaneous melanoma isolated from various body sites including ear, leg, scalp and facial areas. Twelve cell lines have been isolated from mucosal lesions from various body sites including vaginal, ocular, uveal and nasal. In addition, three cell lines were taken and developed from acral melanoma patients.

### **5.2. Cell culture**

The melanoma cell lines were grown and maintained in the tissue culture lab following strict aseptic conditions inside a biosafety cabinet with laminar air flow. In brief, the frozen cell lines were rapidly thawed at 37° C and seeded in DMEM medium containing 10% FBS, antibiotics and anti-fungal agents. The cells were transferred to a 25 mm tissue culture flask containing 7 ml of the DMEM medium, incubated in 5% CO<sub>2</sub> for 24 hours. The flasks were then viewed under the inverted microscope to check if cells attached and to ensure the absence of contamination.



The old medium was then discarded and replaced with fresh DMEM medium. Thereafter, the cells were monitored and medium was change dafter 3 days until the cells achieved 80-90% confluency. The cells were then collected by adding 1 ml of 0.25% trypsin, incubated for 3-5 minutes, and the detached cells were collected in 15 ml sterile conical centrifuge tube. After centrifugation for 7 minutes at low speed (800 x g or 1000 rpm), the supernatant was removed and replaced by 5-10 ml fresh DMEM medium depending on the cell count.

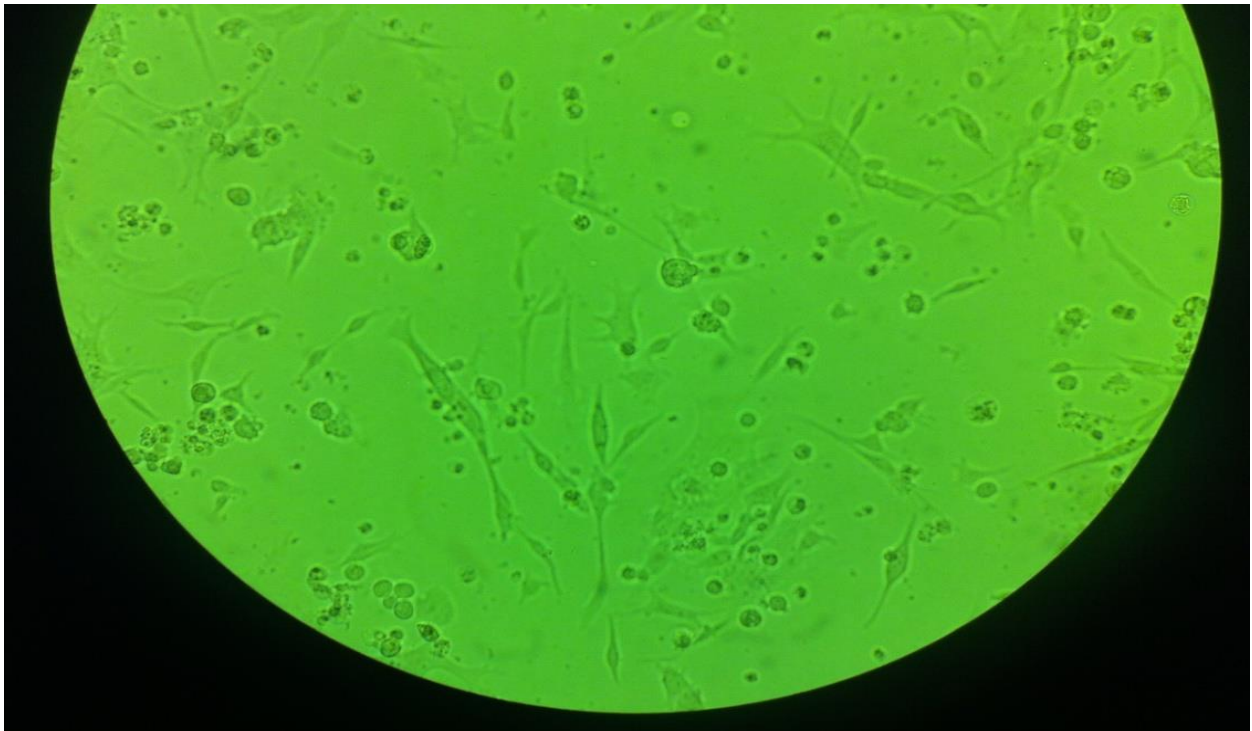


Figure 6: Melanoma cell culture using inverted microscope magnification 10X.

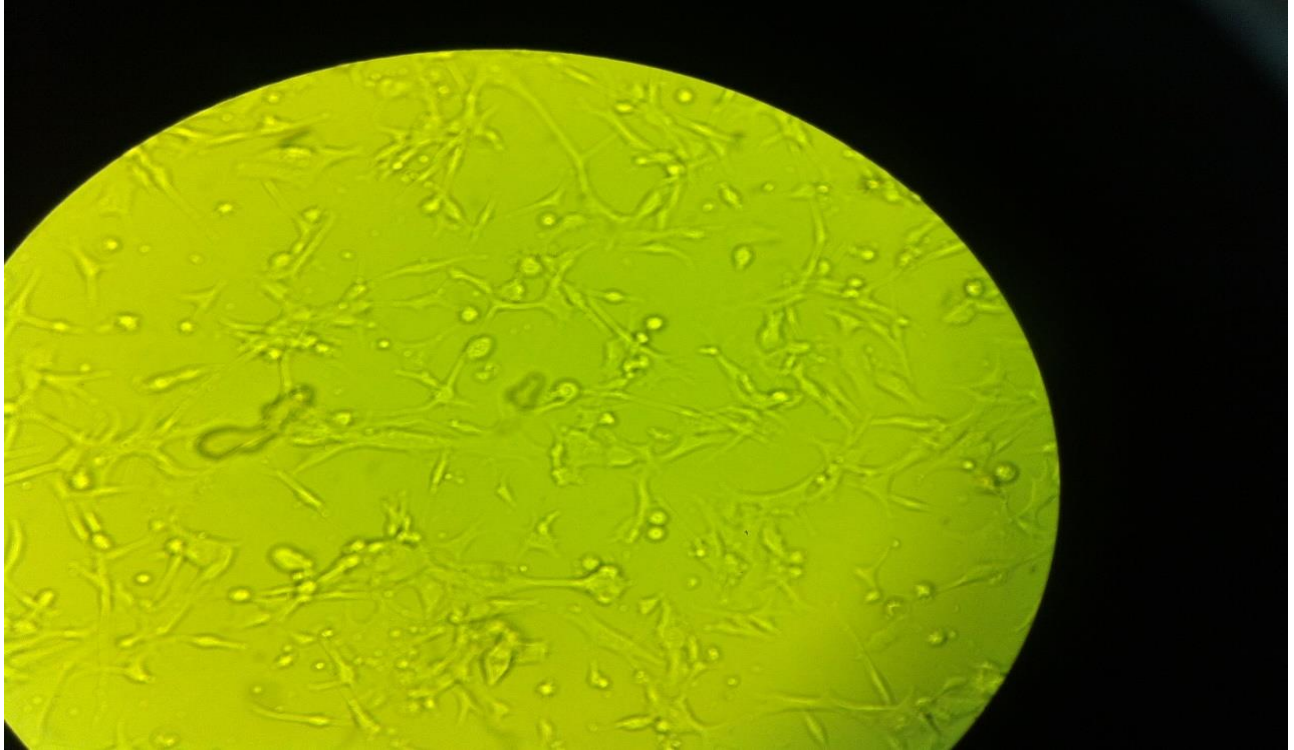


Figure 7: Melanoma cell culture using inverted microscope magnification 10X.

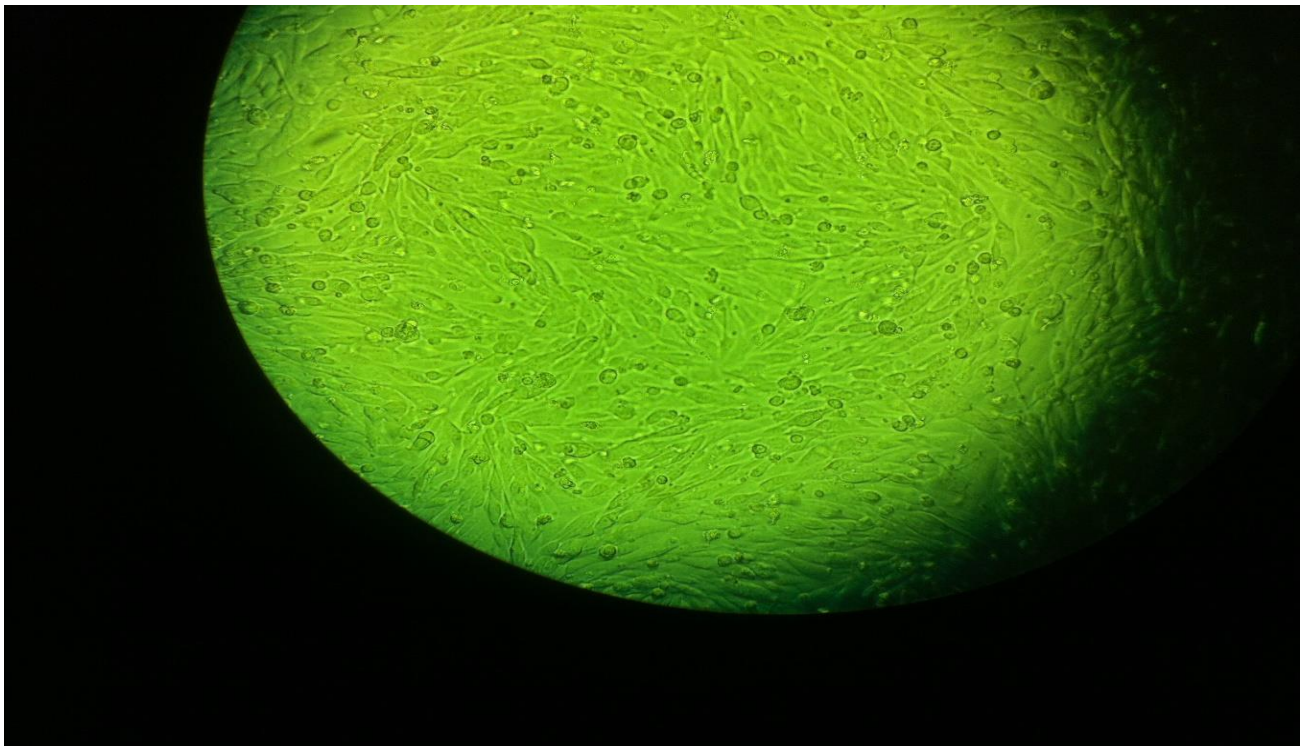


Figure 8: Monolayer of aggressive mucosal melanoma growth after 48 hours.

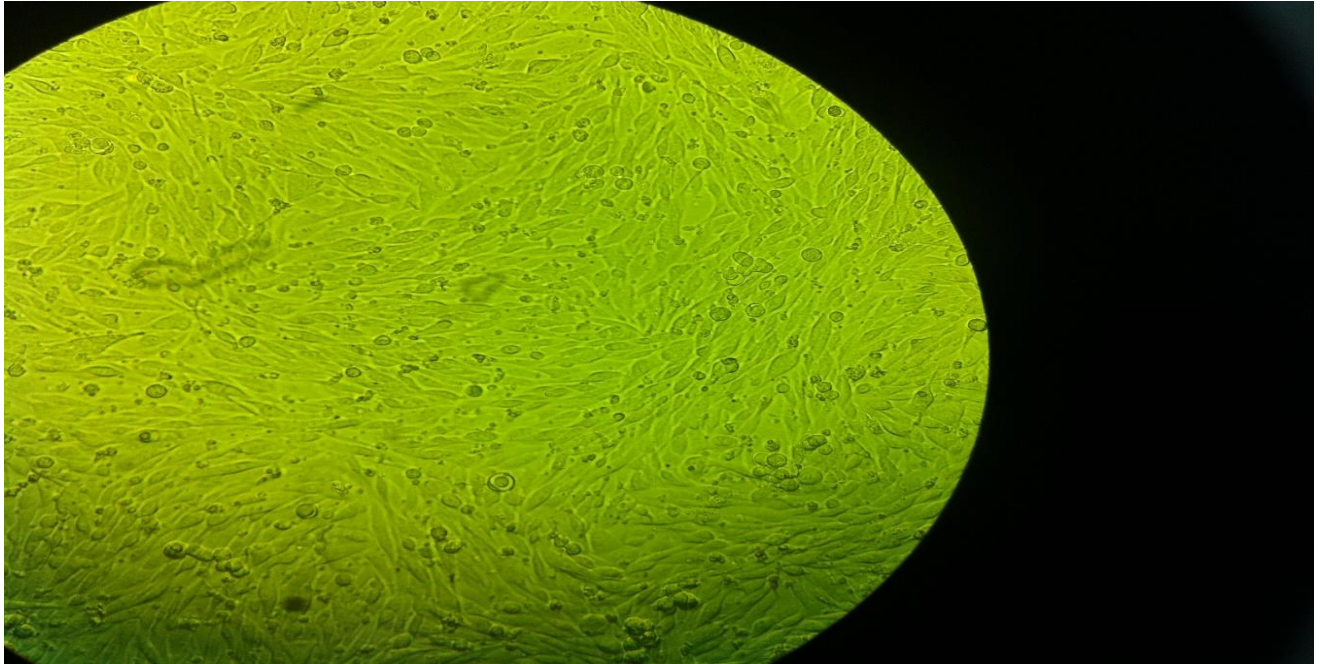


Figure 9: Monolayer of aggressive mucosal melanoma growth after 48 hours.

### **5.3. DNA extraction**

DNA was extracted from the twenty-five cell lines collected by the salting out method according to a standard protocol. One ml of cell suspension was placed in 1.5 ml microcentrifuge tube, centrifuged to sediment the cells and the supernatant removed. This was followed by adding 600  $\mu$ l of TNES buffer to the microcentrifuge tube containing the cells (prepared by mixing 10 mM Tris, pH 7.5 and 100 mM EDTA to regulate the lysate osmolarity and acidity, and 400 mM NaCl, 0.6 % SDS detergent to break up membrane structure and 40  $\mu$ l of

Proteinase-K). Then incubated in a water bath at 55° C for 30 minutes with the microcentrifuge tubes lids are tightly closed and tubes inverted several times to mix the samples. After that, 7 µl of 6 M NaCl were added to the samples and mixed for 20 seconds taking into consideration not to damage the DNA. Then the samples were centrifuged for 5-10 minutes at 12-14000 RPM at room temperature, and the supernatant removed and placed into new 1.5 ml microcentrifuge tubes. Absolute ice-cold ethanol (800 µl) was added to the samples and mixed gently by inverting the tubes several times; the DNA precipitate can be seen as a white string. The samples were then centrifuged at 12-14,000 RPM for 10-20 minutes at 4°C. The pellet containing the DNA was washed by adding 200-700 µl of 100% ethanol by gently inverting the tubes, the ethanol was poured off and samples briefly spun to keep the pellet at the bottom of the tubes.

After repeating the washing step with 70% ethanol as above and removing excess ethanol by centrifugation, (ethanol inhibits the PCR amplification), the samples were left for 10-30 minutes to air dry. The DNA in the samples were finally suspended in 100-200 µl sterile distilled water or Tris-EDTA.

The purified DNA has been examined qualitatively by agarose gel electrophoresis to ensure the presence of intact high quality product. Quantitatively, the yield was determined by nano-drop instrument (Thermo nano-drop) using 260 nm, 280 nm wavelengths. The ratio was determined to ensure the purity of the products.

Then the DNA samples went through normalization process to make all of them get the same concentration 30 ng/ul by distilled water. After that, we used C1000-thermo cycler “Bio-Rad” PCR apparatus, and the samples used the following program:

- Initial denaturation at 94 °C for 5 min followed by 35 cycles of
- Denaturation at 94 °C for 30 seconds
- Annealing at 56 °C for 1 min
- Extension at 72 °C for 1 min.
- Final extension step at 72 °C for 7 min.

Then the PCR products were separated in 2% agarose gel electrophoresis to ensure the quality of the products. The bands were excised, and purified using the QIA quick Gel Extraction Kit (Qiagen). Thereafter, sequencing was carried out using the Big Dye Terminator v1.1 Cycle Sequencing Kit (Applied Bio systems) on a 3130xl Genetic Analyzer (Applied Bio systems).

#### 5.4. Mutational analysis

Screening for possible mutations in the BRAF gene exon 15, NRAS Q61 exon 3, and C-KIT exon 11, 13, and 17 were carried out by PCR and Sanger sequencing. The primers used for amplification and subsequent gene mutations are shown in Table 3.

Oncogene	Primer	Amplicon (bp)	Reference
BRAF (V600E) (exon15)	F-5' TCATAATGCTTGCTCTGATAGGA3' R-5' GGCCAAAAATTTAATCAGTGGA 3'	224 bp	107
NRAS (Q61)	F-5' GAACCAAATGGAAGGTCACA3' R-5' TGGGTAAAGATGATCCGACA3'	301 bp	107
C-KIT (exon11)	F-5' GATCTATTTTTCCCTTTCTC 3' R-5' TTATGTGTACCCAAAAAGG 3'	203 bp	104
C-KIT (exon13)	F-5' -GCGTAAGTTCCTGTATGGTA 3' R-5' AACCTGACAGACAATAAAAAG 3'	237 bp	104
C-KIT (exon17)	F-5' AAAGATTTGTGATTTTGGTCTAGC 3' R-5' GAAACTAAAAATCCTTTGCA.3'	116 bp	104

Table 3: The primers used for each gene mutations

The amplification was carried out in a total volume of 25 ul, consisting of the following: 12.5 ul of 1X ready master mix (containing 0.625 U thermos prime Taq DNA polymerase, 75 mM Tris-HCL (pH 8.8), 20 mM (NH<sub>4</sub>)<sub>2</sub>SO<sub>4</sub>, 0.2 mM dNTPs, 1.5 mM MgCl<sub>2</sub>), 0.28 mM each of forward and reverse primers, 9.3ul distilled water and 2 ul (50ng/ul) Genomic DNA.

## 6. Results

The aim of this work was to determine the types of mutations in cutaneous, mucosal and acral melanoma cell lines isolated from various anatomical sites from Palestinian patients. PCR was performed to obtain products from 5 exons and subsequently sequenced to determine the presence or absence of mutations.

The amounts of DNA extracted from the cell lines ranged from 12.1 to 269.7 ng/ul with an average of 86.3 ng/ul. The ratio of 260/280 was  $\leq 1.8$  indicating a high quality DNA product.

The total numbers of mutations were found in seven cell lines predominantly in cutaneous melanoma. Mutations were detected in 29% (7/24) of the cell lines tested. Most mutations were found in BRAF V600E oncogene in cutaneous mutations of the skin accounting for 57.1% (4/7). Cutaneous mutations of the NRAS Q61R type isolated from ocular tumor was found in 14.2% (1/7) of the cells. Mucosal mutation of the c-KIT oncogene was detected in two cell lines with a rate of 29% (2/7). KIT 11 V559A type was found only in one cell line with a rate 14.2% (1/7). The other mutation was found in KIT13 M651R type in only one cell line with a rate of 14.2% (1/7). The remaining cell lines tested were negative for all tested mutations. The results are summarized in Table 4.

Sample ID	DNA Conc.	Primary Site	BRAF	NRAS	KIT 11	KIT 13	KIT 17
CL001	80.7 ng/ul	Scalp	<b>V600E</b>	WT	WT	WT	WT
CL002	132.9 ng/ul	Leg	WT	WT	WT	WT	WT
CL003	161.2 ng/ul	Mucosal	WT	WT	WT	WT	WT
CL004	93.1 ng/ul	Scalp	<b>V600E</b>	WT	WT	WT	WT
CL005	194.8 ng/ul	Skin of Ear	WT	WT	WT	WT	WT
CL006	195.1 ng/ul	Ocular	WT	<b>Q61R</b>	WT	WT	WT
CL007	73.4 ng/ul	Leg	WT	WT	WT	WT	WT
CL008	87.8 ng/ul	Acral	WT	WT	WT	WT	WT
CL009	269.7 ng/ul	Vagina	WT	WT	WT	WT	WT
CL010	192.3 ng/ul	Acral	WT	WT	WT	WT	WT
CL011	128.9 ng/ul	Scalp	WT	WT	WT	WT	WT
CL012	33.5 ng/ul	Acral	WT	WT	WT	WT	WT
CL013	104.5 ng/ul	Scalp	<b>V600E</b>	WT	WT	WT	WT
CL015	52.3 ng/ul	Mucosal	WT	WT	WT	WT	WT
CL014	79.6 ng/ul	Facial	<b>V600E</b>	WT	WT	WT	WT
CL016	24.5 ng/ul	Uveal	WT	WT	WT	WT	WT
CL017	42.2 ng/ul	Uveal	WT	WT	WT	WT	WT
CL018	16.7 ng/ul	Mucosal	WT	WT	WT	WT	WT
CL019	17.4 ng/ul	Mucosal	WT	WT	WT	<b>M651R</b>	WT
CL020	16.7 ng/ul	Mucosal	WT	WT	WT	WT	WT
CL021	17.3 ng/ul	Mucosal	WT	WT	WT	WT	WT
CL022	24 ng/ul	Mucosal	WT	WT	<b>V559A</b>	WT	WT
CL023	12.1 ng/ul	Uveal	WT	WT	WT	WT	WT
CL024	20 ng/ul	Uveal	WT	WT	WT	WT	WT

Table 4: represents the cell lines tested, DNA concentration and the type of mutations.



Controls for the mutations detected are shown in Figure 10. The sizes of the oncogenes (BRAF, NRAS ,CKIT11, CKIT13, and CKIT17) responsible for the mutations were; 350, 256, 390, 400, 470 and base pairs respectively.

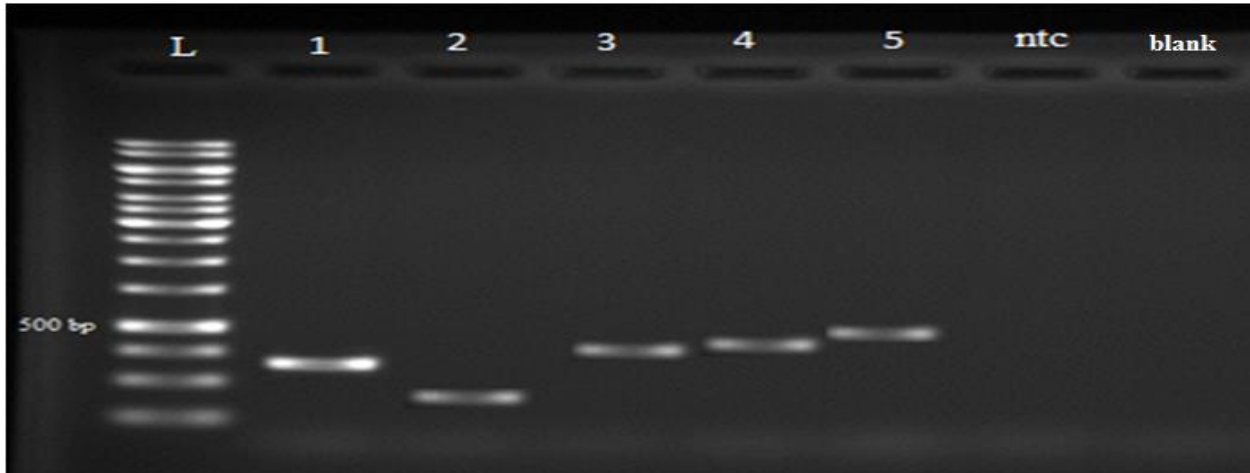


Figure 10: Agarose gel electrophoresis of PCR for controls: Lane "1": BRAF (350 bp), Lane "2": NRAS (256 bp), Lane "3": CKIT 11 (390 bp), Lane "4": CKIT13 (400bp), , Lane"5": CKIT 17 (470 bp) controls

This Figure illustrates the CKIT products for two collections 1 and 2, CKIT 11 and CKIT 13 with sizes ranging from 380-390 bp and 375-400 bp respectively. Samples number 2 and 3 in collection 1 and samples number 2, 3, 4, 6, 8, and 10 in collection 2 are not appear that well so they are repeated in the next figure. In addition to samples number 4, 6, 8 and 10 in collection 1 since unlike other samples they are slightly fading.

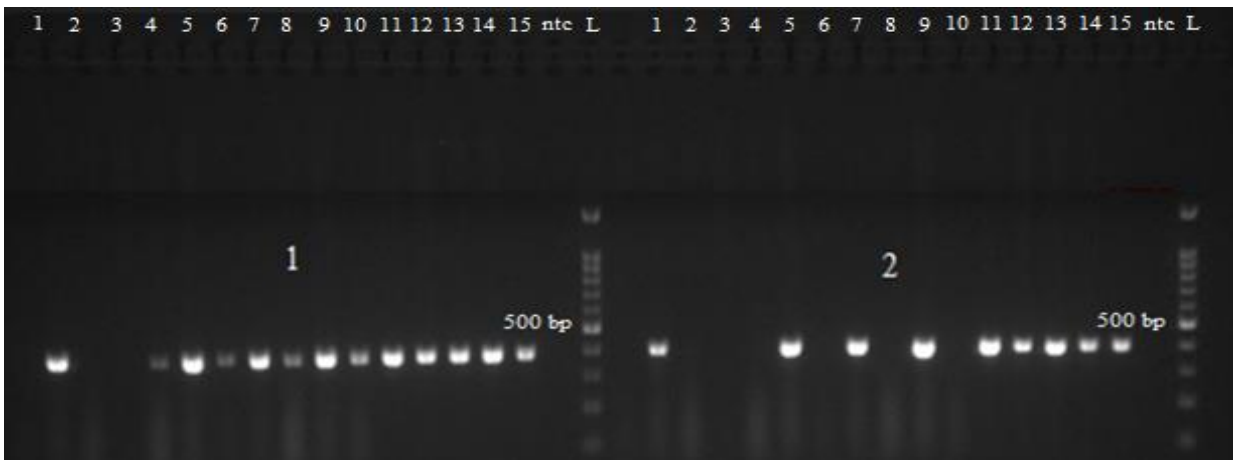


Figure 11: Agarose gel electrophoresis of PCR for Collection "1":CKIT 11, 380-390 bp and Collection "2": CKIT 13, 392-400 bp.

The three collections 1, 2 and 3 show the DNA bands for the unclear ones repeated for CKIT 11, CKIT 13 and unrepeated ones for CKIT 17 with sizes ranging from 392- 397 bp, 395-400 bp, and 465-470 bp respectively.

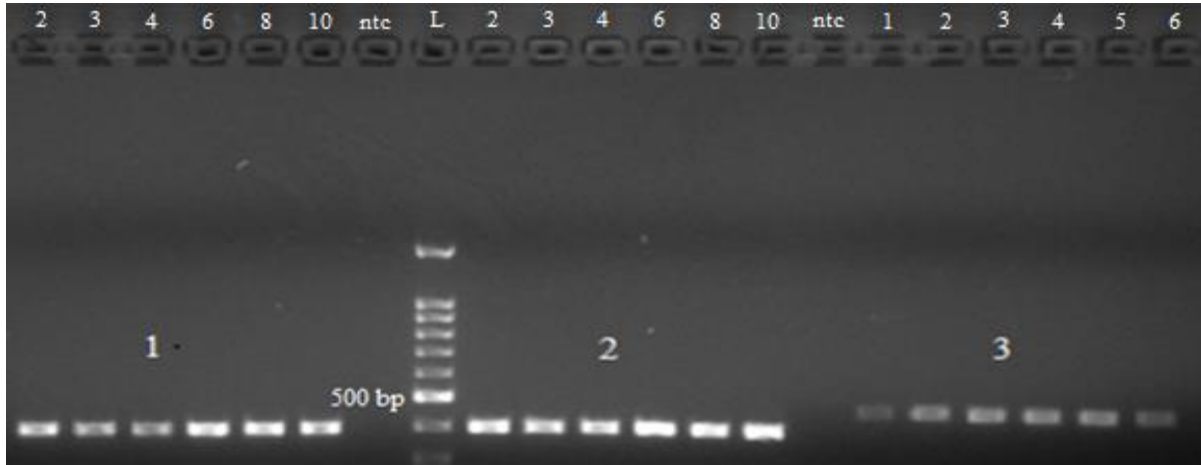


Figure 12: Agarose gel electrophoresis of PCR products for Collection "1": CKIT 11, 392-397 bp, Collection "2" CKIT 13: 395-400 bp, repeated bands and Collection "3" CKIT17: 465-470 bp.

The figure below shows the DNA products for BRAF gene that range in size between 320-350 bp. Band number's 4 appears fading and not clear, so it is repeated again in the next figure.

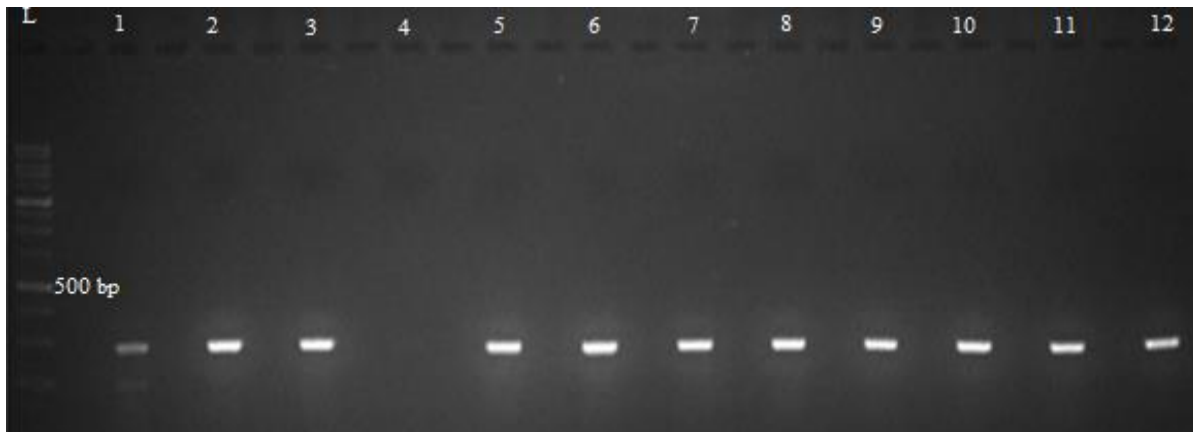


Figure 13: Agarose gel electrophoresis of PCR for BRAF with sizes ranging between 320-350 bp.

The figure below shows the DNA products for BRAF gene samples starting with the repeated one number 4 ranging in size between 320-340 bp.

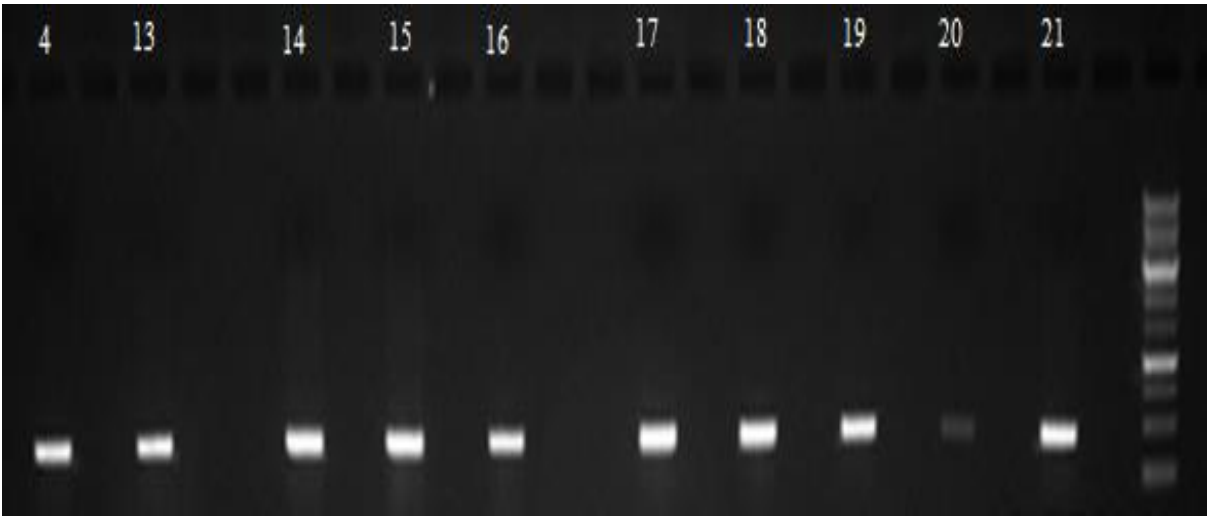


Figure 14: Agarose gel electrophoresis of PCR for BRAF ranging in size between 320-340 bp.

This figure illustrates the NRAS gene products with sizes ranging between 250-256 bp.




Figure 15: Agarose gel electrophoresis of PCR for NRAS 250-256 bp.

This figure shows the WT reverse image for the BRAF Sanger sequencing. The mutation we are looking for should be found in the highlighted area when the sample has mutation.

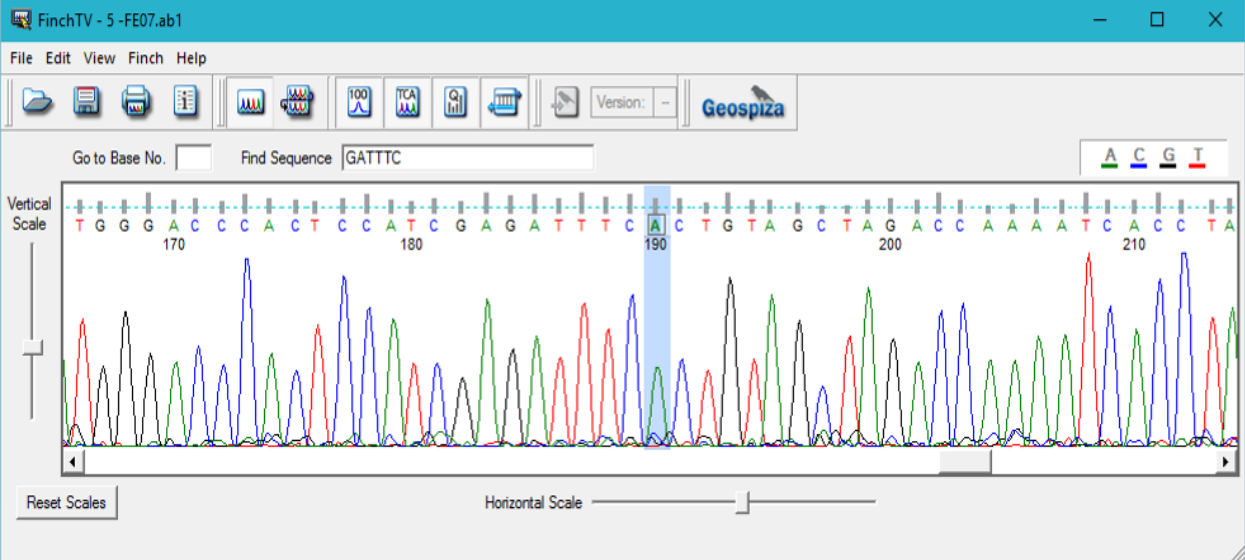


Figure 16: Sanger sequencing of BRAF WT reverse (Bethlehem University, Palestine).

The figure below shows the forward mutation for the BRAF gene in the highlighted area. The mutation found is point mutation BRAF V600E, where glutamic acid is substituted to valine.

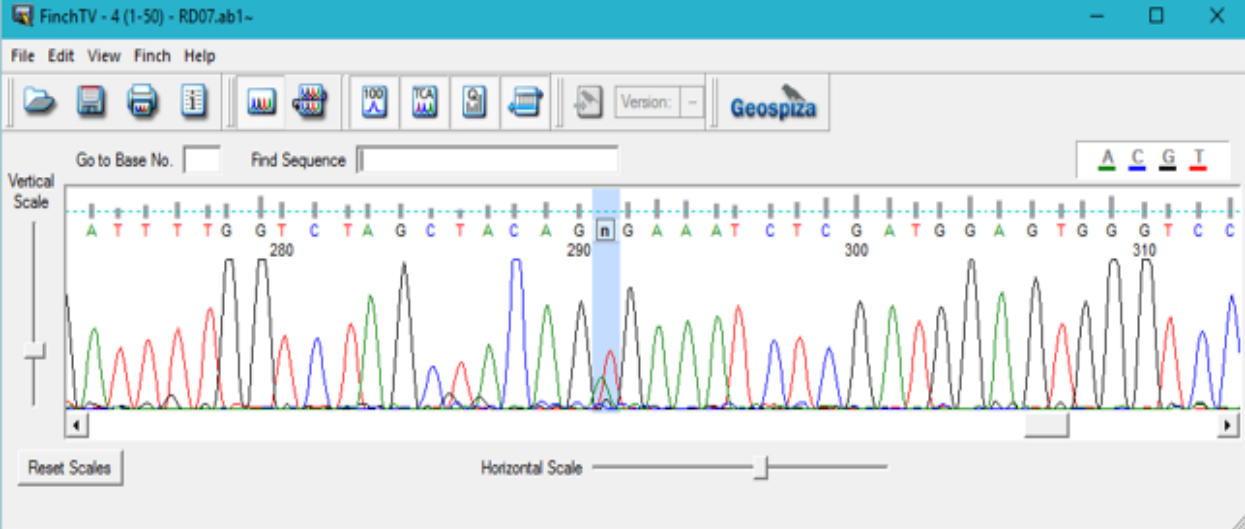


Figure 17: Sanger sequencing of BRAF mutation forward (Bethlehem University, Palestine).

The figure below illustrates the forward WT Sanger sequencing for NRAS gene. Where the suspected mutation should be found in the highlighted area.

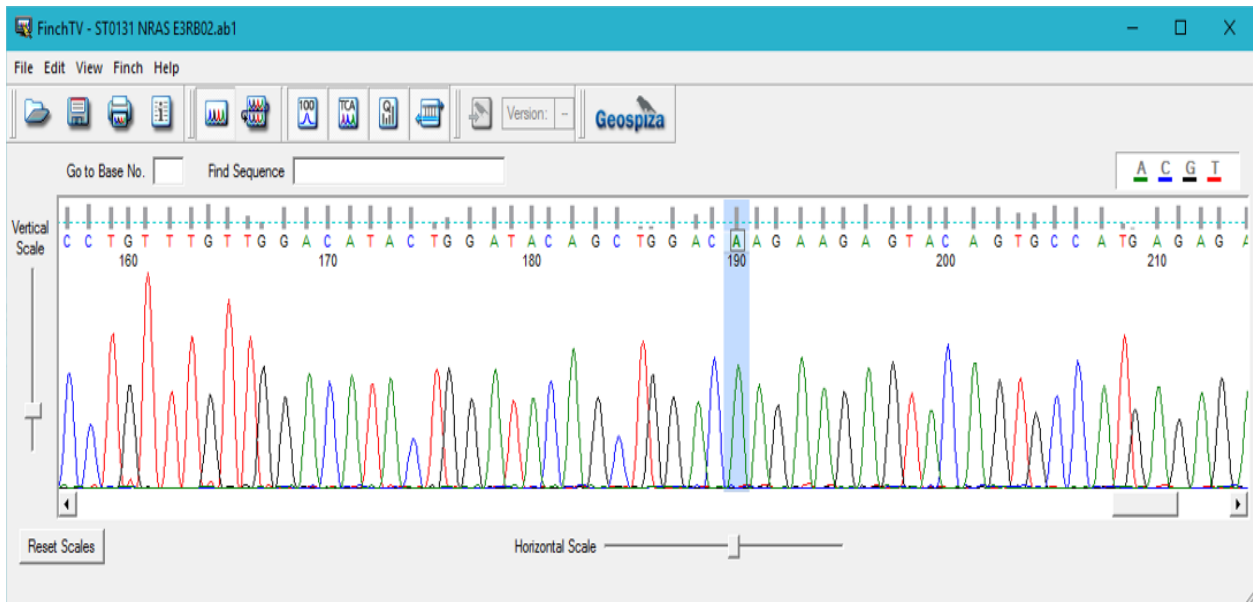


Figure 18: Sanger sequencing of NRAS WT forward (Bethlehem University, Palestine).

This figure shows the reverse WT Sanger sequencing for NRAS gene.

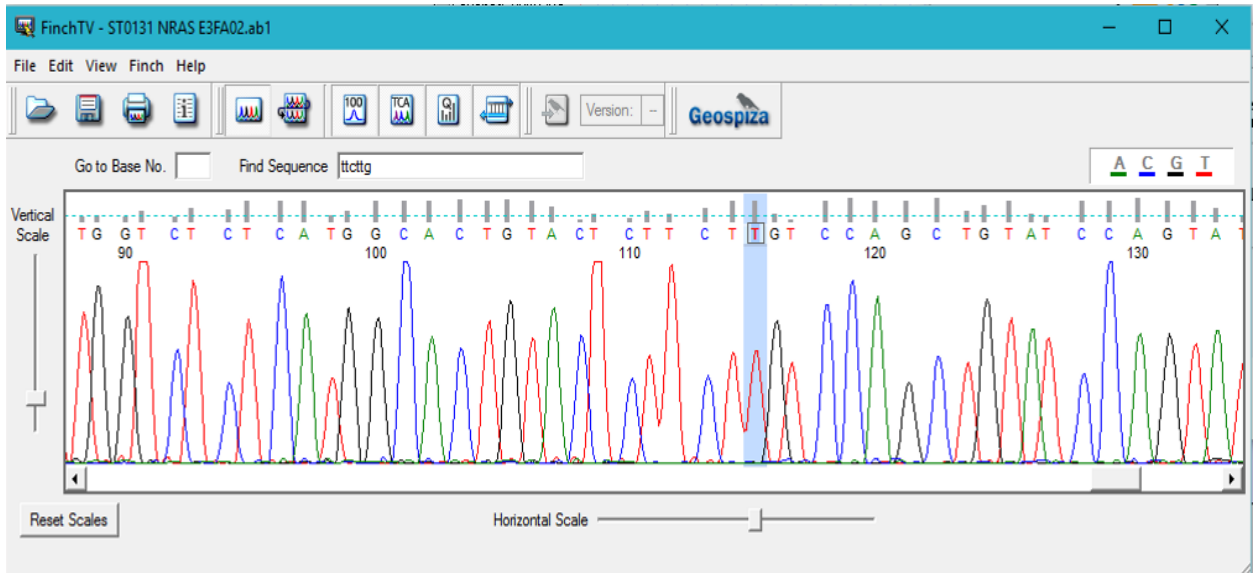


Figure 19: Sanger sequencing of NRAS WT reverse (Bethlehem University, Palestine).

This figure illustrates the highlighted mutational area in NRAS gene forward. The point mutation that found is Q61R where glutamine is substituted to arginine.

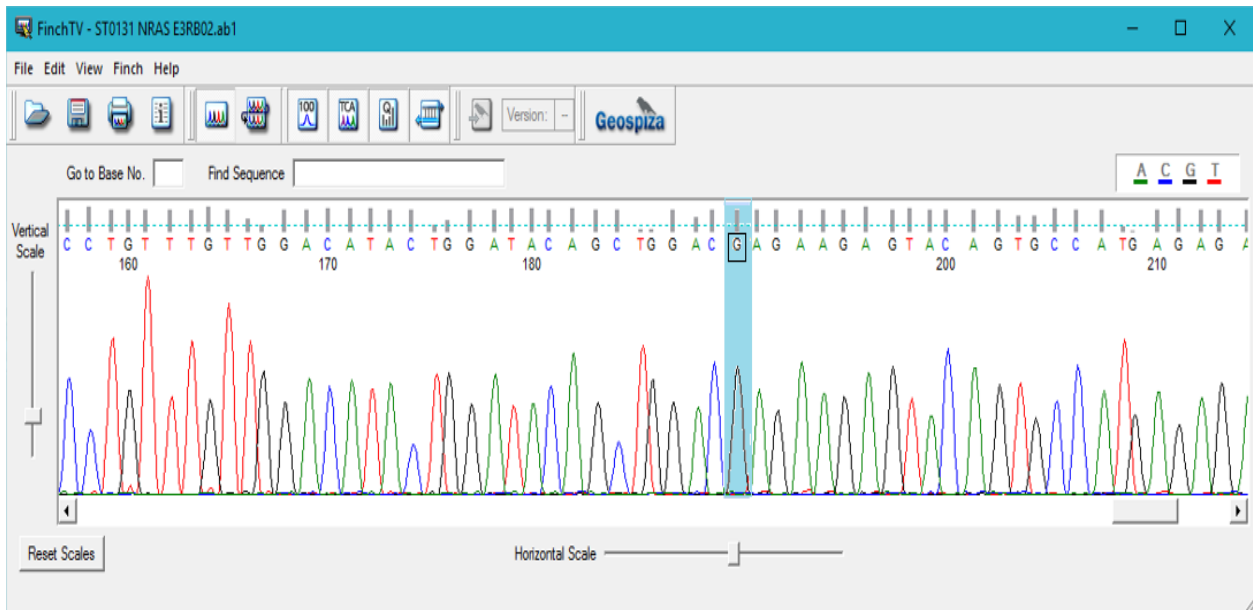


Figure 20: Sanger sequencing of NRAS forward mutation (Bethlehem University, Palestine)

The figure below shows the Sanger sequencing of WT KIT exon 11 L576P. In case of mutational presence there will be a substitution of Leucine to Proline, so we will see C instead of T. This mutation is considered the most common KIT mutation in melanoma with a ratio accounts in range 30-40%<sup>108</sup>.

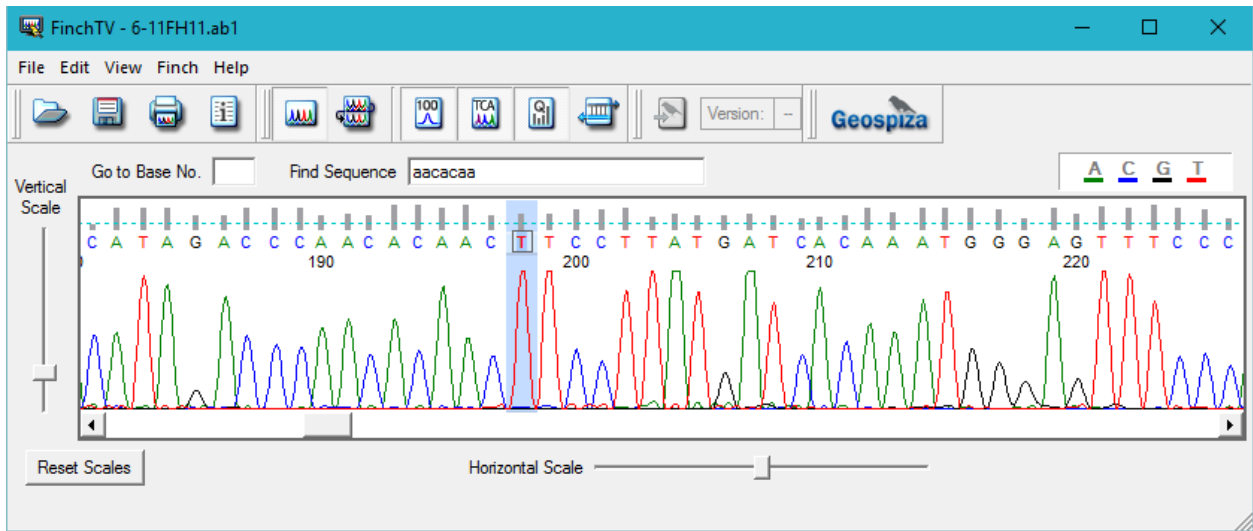


Figure 21: Sanger sequencing of CKIT 11 WT forward (Bethlehem University, Palestine).

The figure below shows the WT Sanger sequencing for KIT exon 11 V559A.

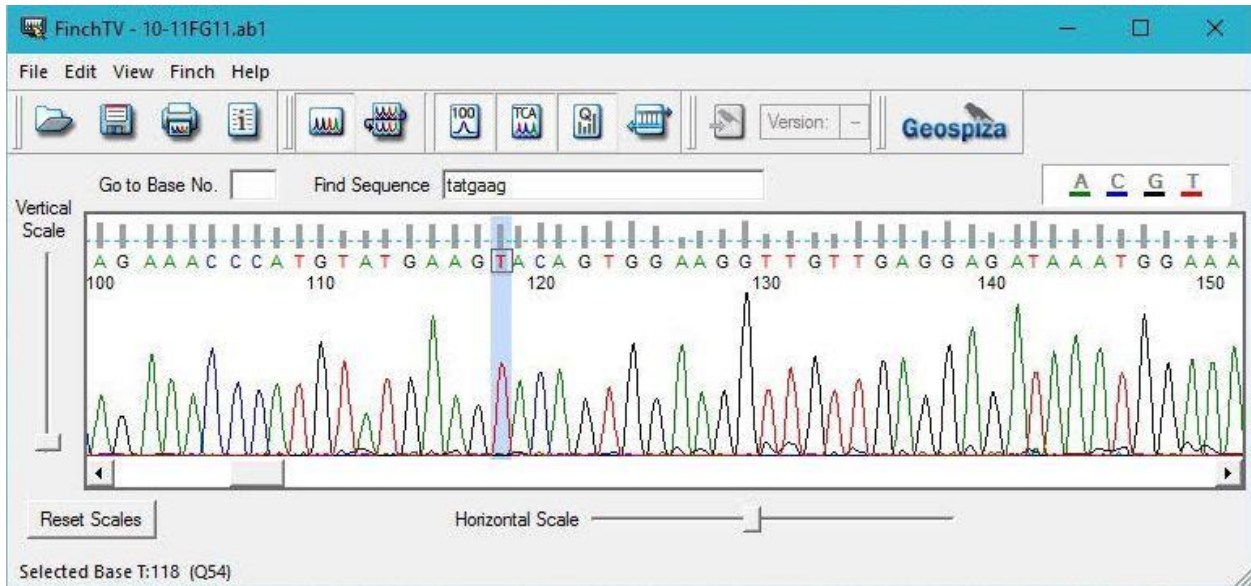

Figure 22: Sanger sequencing of CKIT 11 WT forward (Bethlehem University, Palestine).

The figure below illustrates the mutational form for the previous WT mutation, where the mutation found is V559A, a substitution of Valine to Alanine at position 559. This mutation accounts around 20% of MM.

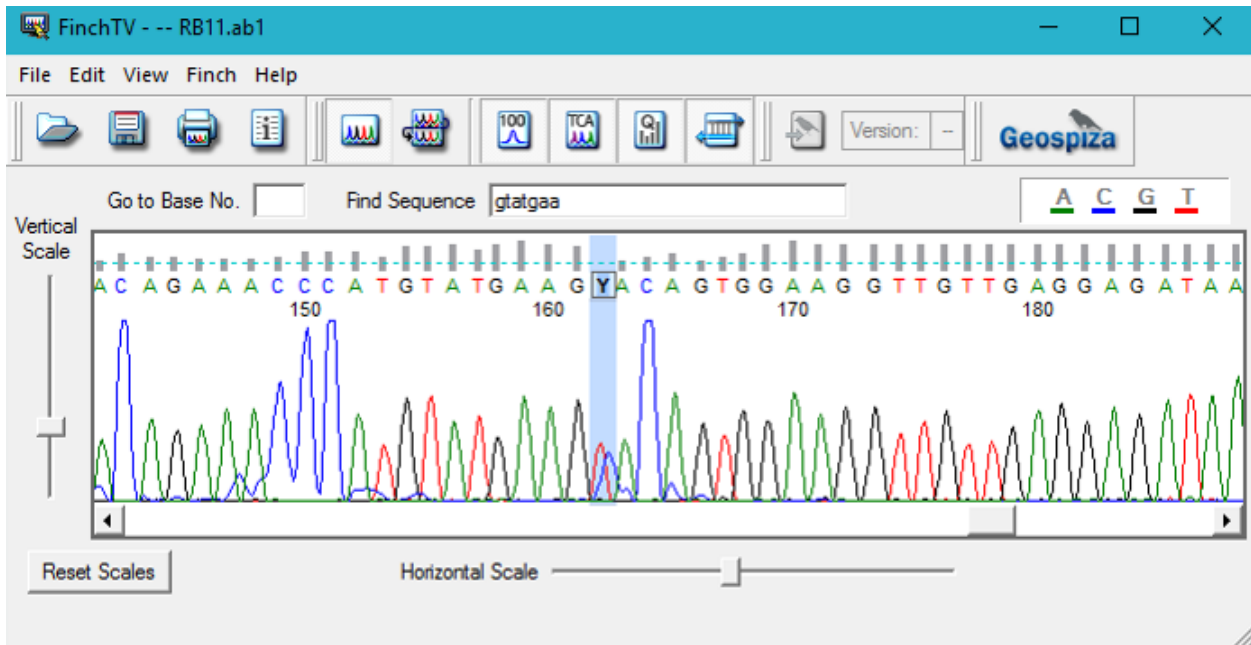

Figure 23: Sanger sequencing of CKIT 11 mutation (Bethlehem University, Palestine).

This figure illustrates the WT exon 13 of K642E substitution of Lysine to Glutamic acid. If there is a mutation the highlighted A will convert to G. this mutation accounts up to 20% of MM<sup>109</sup>.

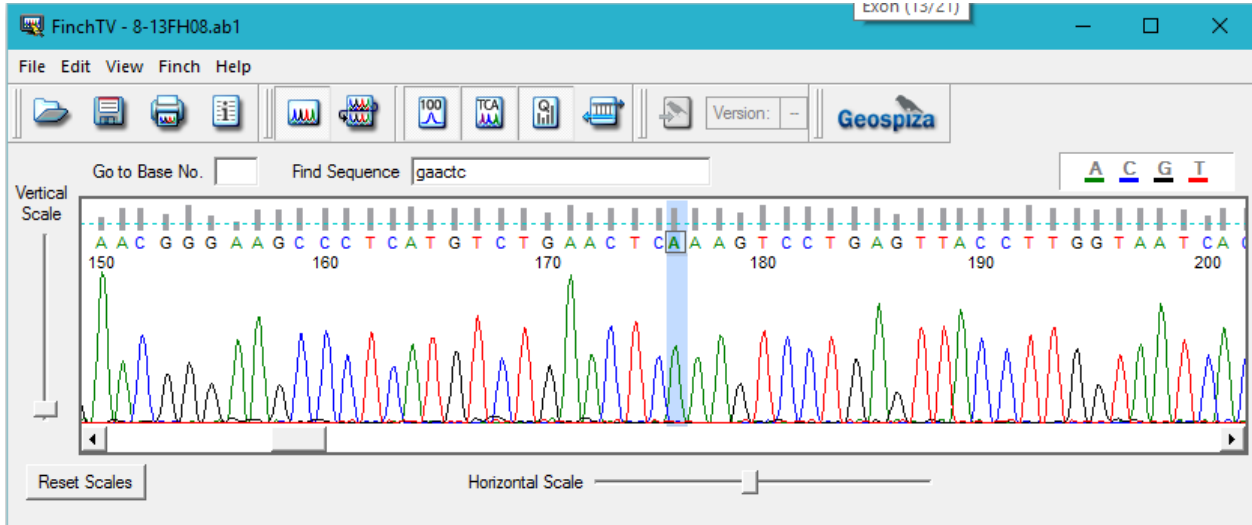


Figure 24: Sanger sequencing of CKIT 13 WT (Bethlehem University, Palestine).

The figure below shows the forward WT Sanger sequencing of CKIT 13.

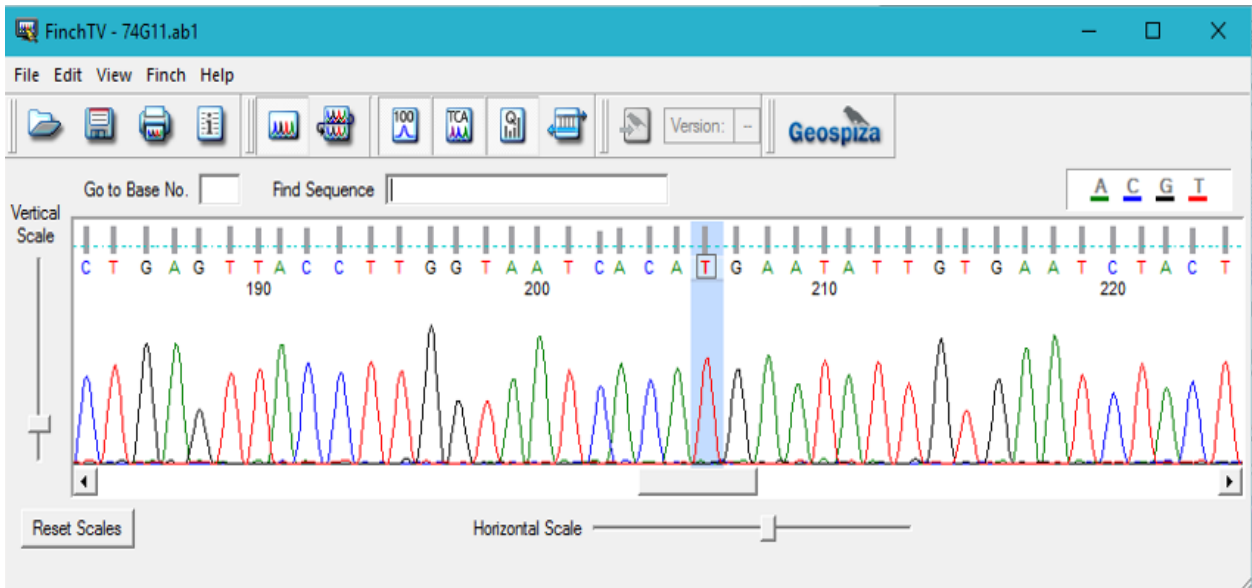


Figure 25: Sanger sequencing of KIT 13 WT (Bethlehem University, Palestine).



This figure shows M651R mutation that found in Sanger sequencing of CKIT 13. This mutation is result from substitution of Methionine to Arginine, and it not found in litreture therefore it is maybe considered as norval mutation.

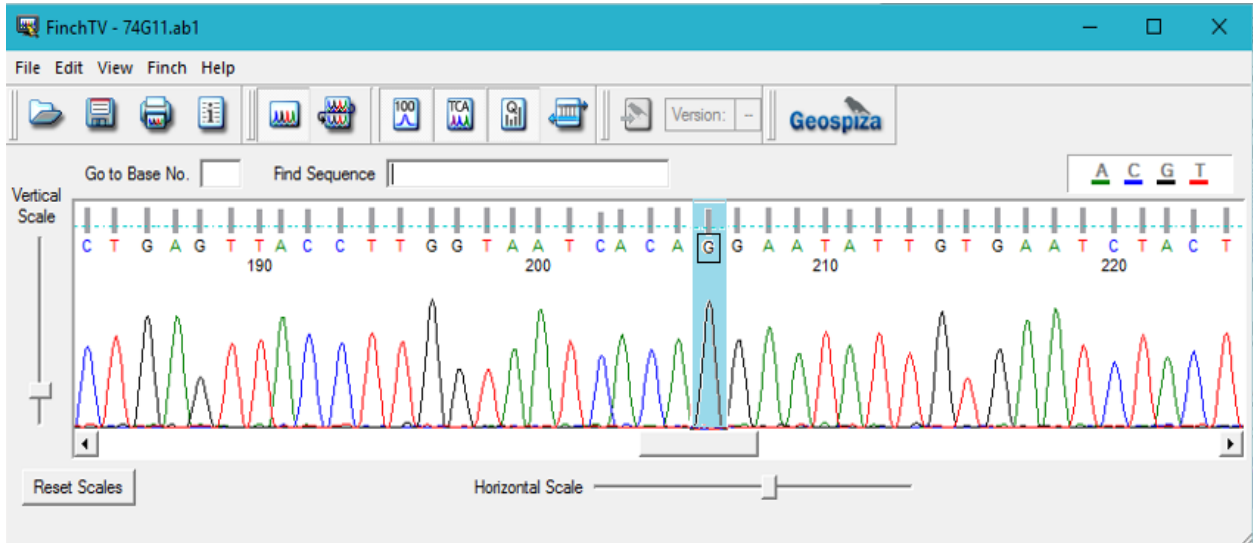


Figure 26: Sanger sequencing of CKIT 13 mutation (Bethlehem University, Palestine).

The figure below illustrates the WT Sanger sequencing of D816H exon 17. In case of mutational presence, there will be an amino acid substitution from an Aspartic acid to Histidine.

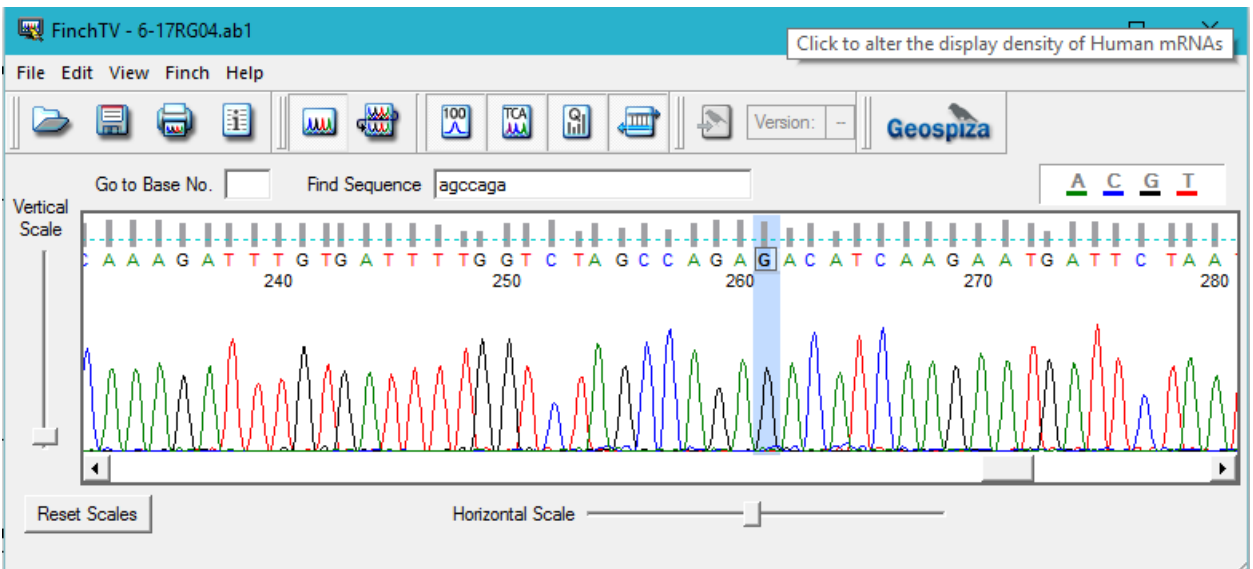


Figure 27: Sanger sequencing of CKIT 17 WT (Bethlehem University, Palestine).

## 7. Discussion

This work has been conducted on 24 cell lines established from Palestinian patients with melanoma, which included cutaneous and mucosal types. The aim of the study was to determine the type and rate of mutations in these cell lines.

The identification of gene mutations in all types of melanoma (CM, MM) from various body sites has provided significant information regarding the progression of molecular target therapies for this disease. These mutations have been identified to occur in multiple oncogenes primarily BRAF, GNAQ, KIT, MEK1 (MAP2K1) and NRAS. Mutations in these oncogenes were the most common and found in about 70% of all melanoma mutations. However, Somatic mutations in GNA11 and GNAQ have been primarily identified in uveal melanoma and its metastasis<sup>110</sup>. Furthermore, somatic mutations in MEK1(MAP2K1) have been found in 6% of malignant melanomas<sup>111</sup>, but their prevalence in melanoma subtypes has not yet been determined. The therapeutic role that MEK1 mutations is extremely low<sup>112</sup>. Therefore, these genes were not included in the panel of oncogenes (BRAF, NRAS and KIT subtypes) investigated in this project.

Our data in this study showed that the most common oncogene mutation incriminated in cutaneous melanoma was BRAF V600E, where glutamic acid is substituted to valine, which accounted for 66.7% (4/6). This finding is close to the rate reported for somatic mutations in BRAF of 20-80% as mentioned above. The second and third most common mutations reported after BRAF V600E were BRAFV600K and BRAFV600R respectively. These mutations have not been detected in the sample tested in this study. The head and neck melanoma are the most common sites where cutaneous melanoma occurs in men<sup>113</sup>.

BRAF mutations are mainly involved in the induction of genomic instability, and enhancing with a high frequency the melanocytes proliferation, e.g. the mutated BRAF signals as an autonomous monomer of upstream growth stimuli, especially in BRAF V600E, which causes kinase activation as well as negative feedback mechanics insensitivity. This mutation is also involved in other mechanisms related to melanoma progression, mainly the downstream MEK/ERK pathway activation, apoptosis and senescence elusion. In addition to that, it plays an important role in tissue invasion and metastasis by up regulation of many proteins that are implicated in cell contractility, migration, integrin signaling, tumor and microenvironment- derived interleukin-8, as well as angiogenesis by MEK-dependent activation of HIK-11 $\alpha$  and VEGF<sup>114</sup>.

Another oncogene that has been investigated in this study was NRAS. Somatic mutations in this oncogene have been reported in about 13-25% of all malignant melanomas<sup>115</sup>. In this study, the rate of somatic mutations in NRAS oncogene in the tested cell lines was 14.2% (1/7), similar to that reported in literature. It has been known that mutations in NRAS Q61 oncogene occurring in exon 3 are missense mutations resulting in the substitution of amino acids at positions 12, 13 or Q61. Glutamine residue is usually substituted by lysine or arginine. Although somatic mutations in both BRAF and NRAS oncogenes are associated strongly with UV light, the NRAS mutations do not overlap with other mutations caused by other oncogenes such as BRAF and KIT.

BRAF and NRAS sharing the same pathway, consequently one of them or both could be activated according to the pathway track. Since the MAP kinase signaling pathway activates set up an obligatory step in the transformation of melanocytes, and small interfering RNA “siRNA” depleting B-raf in BRAF V600E melanocytes as well as siRNA mediating silencing of N-ras in NRAS codon 61 mutant melanocytes inhibits Erk activation and results in apoptosis. Based on that NRAS considered the second most common oncogenic driver mutation in melanoma.

Hence, the intracellular pathway has been activate and induces cell cycle dysregulation, pro-survival pathways, and cellular proliferation<sup>116</sup>.

Somatic mutations in KIT oncogene have been reported in all melanoma subtypes. However, these mutations are most common in acral melanomas at rate of 10-20% and the gene encoding receptor tyrosine kinase KIT mutations and or increased in copy numbers have been seen in up to 40% of MM<sup>117, 118</sup>.The KIT oncogene encodes a protein that functions in controlling cell division. It causes abnormalities in several areas such as nail beds, palms, soles or mucous membranes. Somatic mutations on KIT gene are not associated with UV light. The most common mutations, which could be found in MM, are L576P that accounts the highest mutational ratio, followed by K642E, V559A, and D816H. These mutations account around 50% of all KIT mutations in literature.

The rate of KIT mutations observed in this study was 29% (2/7) which is similar to that reported in literature as mentioned previously. As reported, this oncogene causes melanomas in several body sites including mucous membranes. The first mutation has been detected in CL022 that has been established from mucosal melanoma site. This mutation appeared in KIT 11 by substitution of Valine to Alanine at position 559. This mutation accounts around 20% of all MM.<sup>119</sup> The

second mutation has been detected in the cell line number CL019 which was established from a mucosal melanoma case too. This mutation appeared in KIT13 by substitution of methionine to arginine at position 651. Somatic mutations for KIT17 were not detected in the cell lines tested. The frequency of KIT mutations in primary MM varies notably with its anatomical site, respiratory, gastrointestinal and urogenital tracts. The Kit mutations are typically amino acid substitutions in 11, 13 or 17 exons, while the KIT mutation which is found in gastrointestinal melanocytes occur as a results of deletion or insertion in exon 11<sup>120</sup>. The KIT mutations in melanocytes consequently affect the juxtamembrane domain of the KIT protein leading to constitutive activation of KIT ligand binding of the tyrosine kinase of C-KIT independently<sup>121</sup>.

This mutation is not found in literature therefore it is maybe considered as novel mutation.

In general, mucosal and acral melanomas are considered the most common subtypes in Asian population<sup>122</sup>. This comprises greater than 70% of all melanomas, a rate that is much higher than that seen in white populations<sup>123</sup>. Therefore, c-Kit mutations are likely the most common kind of genetic mutations in Asians, and the investigation of c-Kit inhibitors is a high priority in this population<sup>124</sup>.

Only few researches have been published related to this field in Arab's world. In Jordan, there are no previous comprehensive Jordanian studies on melanoma and proper statistical data on morbidity and incidence are nonexistent<sup>125</sup>. However, they studied the histopathology records of CM samples in 2008 and analyzed them in accordance to their clinical data, to evaluate their experience in CM at King Hussein Medical Center<sup>126</sup>. Nevertheless, there are no studies about MM. While in Lebanon, they recently studied the rate of different BRAF mutation types, and assessed correlations with prognostic markers and potential UVR exposure<sup>127</sup>. In addition, there are some studies in diagnosis of melanoma to assess the frequency of occurrence and risk factors for MM<sup>128</sup>. There is no specific study about MM, but there are some studies about treatment of MM, Imatinib in patients with mucosal or acral lentiginous melanoma, to evaluate how effective Imatinib in treating these types of melanoma in patients whose disease carries a c-kit mutation<sup>129</sup>.

In Egypt, the incidence rate of melanoma is very low and its topographic distribution is different<sup>130</sup>. For this reason, melanoma studies are rare there, so they studied the extra cutaneous malignant melanomas, reporting several cases<sup>131</sup>. In addition, they studied the molecular mechanisms for melanoma and other skin cancers caused by UV radiation<sup>132</sup>. immunohistochemical expression in CM such

as Ephrin A4<sup>133</sup>, also its association with hepatitis C virus<sup>134</sup>. No articles have been published about MM; only in 2014, they published case report about gastric metastases from invasive MM<sup>135</sup>. As for Saudi Arabia, they published an article in 2012 studied CM from 1995-2011 at King AbdulAziz university hospital, found that CM accounts 11.5% of population while 68.7% are ALM<sup>136</sup>. In Iraq, they published last year an article about melanomas there, and they found that the most common and aggressive one is the ALM 75%, with a lesser amount of CM<sup>137</sup>, no direct studies about MM there. However, in Iran they studied MM, to investigate incidence, sex, age and site distribution of MM of the head and neck<sup>138</sup>.

In Tel Aviv university Sourasky medical center/Israel, they published an article about two p16 (CDKN2A) germ line mutations in 30 Israeli melanoma families<sup>139</sup>. Another two cases report in rectal malignant melanoma have been published in Carmel medical center, Haifa<sup>140</sup>. While in Hadassah university hospital, Jerusalem they studied MM in nine cases of the female genital tract<sup>141</sup>.

In Palestine no studies have been done in MM neither CM. for this reason we want to make a study on this subject, and compare between CM and MM/ ALM mutations at the molecular level.



## References

---

- <sup>1</sup>Meguerditchian AN, Asubonteng K, Young C, Lema B, Wilding G and Kane JM, 3rd. Thick primary melanoma has a heterogeneous tumor biology: an institutional series. *World J SurgOncol.* 2011; 9:40.
- <sup>2</sup> Houghton AN, and Polsky D. Focus on melanoma. *Cancer Cell.* 2002; 2:275-278
- <sup>3</sup>Shenenberger, Donald W. "Cutaneous malignant melanoma: a primary care perspective." *American family physician* 85.2 (2012): 161-168.
- <sup>4</sup>Sladden MJ, Balch C, Barzilai DA, et al. Surgical excision margins for primary cutaneous melanoma. *Cochrane Database Syst Rev.* 2009;(4):CD004835.
- <sup>5</sup> Miller AJ and Mihm MC, Jr. Melanoma. *N Engl J Med.* 2006; 355:51-65.
- <sup>6</sup>Hazen, Brent P., et al. "The clinical diagnosis of early malignant melanoma: expansion of the ABCD criteria to improve diagnostic sensitivity." *Dermatology online journal* 5.2 (1999).
- <sup>7</sup> Moore P, Hundley J, Hundley J, et al. Does shave biopsy accurately predict the final breslow depth of primary cutaneous melanoma? *Am Surg.* 2009;75(5):369-373, discussion 374.
- <sup>8</sup>Bono, Aldo, et al. "The ABCD system of melanoma detection." *Cancer* 85.1 (1999): 72-77.
- <sup>9</sup>Berrocal, Alfonso, et al. "Melanoma: diagnosis, staging, and treatment. Consensus group recommendations." *Advances in therapy* 31.9 (2014): 945-960.
- <sup>10</sup> Tran KT, Wright NA, Cockerell CJ. Biopsy of the pigmented lesion—when and how. *J Am AcadDermatol.* 2008;59(5):852-871.
- <sup>11</sup>Salerni, Gabriel, et al. "The role of dermoscopy and digital dermoscopy follow-up in the clinical diagnosis of melanoma: clinical and dermoscopic features of 99 consecutive primary melanomas." *Dermatology practical & conceptual* 4.4 (2014): 39.
- <sup>12</sup>Swanson, Neil A., et al. "Biopsy techniques: diagnosis of melanoma." *Dermatologic clinics* 20.4 (2002): 677-680.
- <sup>13</sup>Roberts, D. L. L., et al. "on behalf of the British Association of Dermatologists, Bishop JAN, Corrie PG, Evans J, Gore ME, Hall PN, Kirkham N on behalf of the Melanoma Study Group. UK guidelines for the management of cutaneous melanoma." *Br J Dermatol* 146 (2002): 7-17.
- <sup>14</sup>Tadiparthi, S., S. Panchani, and A. Iqbal. "Biopsy for malignant melanoma—are we following the guidelines?." *Annals of the Royal College of Surgeons of England* 90.4 (2008): 322.

- 
- <sup>15</sup>Šitum, Mirna, et al. "Melanoma—Clinical, Dermatoscopic, and Histopathological Morphological Characteristics." *Acta Dermatovenerologica Croatica* 22.1 (2014): 2-2.
- <sup>16</sup>Garbe, Claus, and Ulrike Leiter. "Melanoma epidemiology and trends." *Clinics in dermatology* 27.1 (2009): 3-9.
- <sup>17</sup>Skender-Kalnenas, Theresa M., Dallas R. English, and Peter J. Heenan. "Benign melanocytic lesions: risk markers or precursors of cutaneous melanoma?." *Journal of the American Academy of Dermatology* 33.6 (1995): 1000-1007.
- <sup>18</sup>Kalkhoran, Sara, et al. "Historical, clinical, and dermoscopic characteristics of thin nodular melanoma." *Archives of dermatology* 146.3 (2010): 311-318.
- <sup>19</sup>Greenwald, Holly S., Erica B. Friedman, and Iman Osman. "Superficial spreading and nodular melanoma are distinct biological entities: a challenge to the linear progression model." *Melanoma research* 22.1 (2012): 1.
- <sup>20</sup>Warycha, Melanie A., et al. "Changes in the presentation of nodular and superficial spreading melanomas over 35 years." *Cancer* 113.12 (2008): 3341-3348.
- <sup>21</sup>Zalaudek, Iris, et al. "Three roots of melanoma." *Archives of dermatology* 144.10 (2008): 1375-1379.
- <sup>22</sup>Kelly, John W., et al. "Nodular melanoma." No longer as simple as ABC. *Aust Fam Phys* 32 (2003): 706-709.
- <sup>23</sup>Cohen, Lisa M. "Lentigomaligna and lentigomaligna melanoma." *Journal of the American Academy of Dermatology* 33.6 (1995): 923-936.
- <sup>24</sup>Walling, Hobart W., et al. "Staged excision versus Mohs micrographic surgery for lentigomaligna and lentigomaligna melanoma." *Journal of the American Academy of Dermatology* 57.4 (2007): 659-664.
- <sup>25</sup>Swetter, Susan M., et al. "Increasing incidence of lentigomaligna melanoma subtypes: northern California and national trends 1990–2000." *Journal of investigative dermatology* 125.4 (2005): 685-691.
- <sup>26</sup>Clark Jr, Wallace H., and Martin C. Mihm Jr. "Lentigomaligna and lentigo-maligna melanoma." *The American journal of pathology* 55.1 (1969): 39.
- <sup>27</sup>Harmelin, Eric S., et al. "Acral lentiginous melanoma." *The Journal of foot and ankle surgery* 37.6 (1998): 540-545.
- <sup>28</sup>Nagore, Eduardo, et al. "Acral lentiginous melanoma presents distinct clinical profile with high cancer susceptibility." *Cancer Causes & Control* 20.1 (2009): 115-119.

- 
- <sup>29</sup>Krementz, EDWARD T., et al. "Acral lentiginous melanoma. A clinicopathologic entity." *Annals of surgery* 195.5 (1982): 632.
- <sup>30</sup>Cascinelli, Natale, et al. "Acral Lentiginous Melanoma." *The Journal of dermatologic surgery and oncology* 20.12 (1994): 817-822.
- <sup>31</sup>Schoenewolf, Nicola, et al. "Acrolentiginous melanomas." *Journal of the Egyptian Women's Dermatologic Society* 8.2 (2011): 55-62.
- <sup>32</sup>Bradford, Porcia T., et al. "Acral lentiginous melanoma: incidence and survival patterns in the United States, 1986-2005." *Archives of dermatology* 145.4 (2009): 427-434.
- <sup>33</sup>Puig-Butillé, Joan A., et al. "Genetic alterations in RAS-regulated pathway in acral lentiginous melanoma." *Experimental dermatology* 22.2 (2013): 148-150.
- <sup>34</sup>Dai, Bo, et al. "Analysis of KIT expression and gene mutation in human acral melanoma: with a comparison between primary tumors and corresponding metastases/recurrences." *Human pathology* 44.8 (2013): 1472-1478.
- <sup>35</sup>Boniol, Mathieu, et al. "Cutaneous melanoma attributable to sunbed use: systematic review and meta-analysis." *Bmj* 345 (2012).
- <sup>36</sup>Platz, Anton, et al. "Human cutaneous melanoma; a review of NRAS and BRAF mutation frequencies in relation to histogenetic subclass and body site." *Molecular oncology* 1.4 (2008): 395-405.
- <sup>37</sup>Daya-Grosjean, Leela, Nicolas Dumaz, and Alain Sarasin. "The specificity of p53 mutation spectra in sunlight induced human cancers." *Journal of Photochemistry and Photobiology B: Biology* 28.2 (1995): 115-124.
- <sup>38</sup>Ito, K., and S. Kawanishi. "Site-specific DNA damage induced by UVA radiation in the presence of endogenous photosensitizer." *Biological chemistry* 378.11 (1997): 1307-1312.
- <sup>39</sup>Zhang, Mingfeng, et al. "Use of tanning beds and incidence of skin cancer." *Journal of Clinical Oncology* 30.14 (2012): 1588-1593.
- <sup>40</sup>Dummer, R., et al. "Cutaneous melanoma: ESMO Clinical Practice Guidelines for diagnosis, treatment and follow-up." *Annals of Oncology* 23.suppl 7 (2012): vii86-vii91.
- <sup>41</sup>Mihajlovic, Marija, et al. "Primary mucosal melanomas: a comprehensive review." *International journal of clinical and experimental pathology* 5.8 (2012): 739.

---

<sup>42</sup>Postow, Michael A., Omid Hamid, and Richard D. Carvajal. "Mucosal melanoma: pathogenesis, clinical behavior, and management." *Current oncology reports* 14.5 (2012): 441-448.

<sup>43</sup> McLaughlin CC, Wu XC, Jemal A, Martin HJ, Roche LM. Incidence of noncutaneous melanomas in the U.S. *Cancer*. 2005 Mar 1; 103(5):1000-7.

<sup>44</sup> Thompson LD, Wieneke JA, Miettinen M. *Am J SurgPathol*. 2003. Sinonasal tract and nasopharyngeal melanomas: a clinicopathologic study of 115 cases with a proposed staging system. May; 27(5):594-611.

<sup>45</sup>Ravi, A. 2008. Primary gastric melanoma: a rare cause of upper gastrointestinal bleeding. *GastroenterolHepatol (N Y)*. Nov; 4(11):795-7.

<sup>46</sup> Reid GC, Schmidt RW, Roberts JA, Hopkins MP, Barrett RJ, Morley GW. *Obstet Gynecol*. 1989. Primary melanoma of the vagina: a clinicopathologic analysis. Aug; 74(2):190-9.

<sup>47</sup>ALLEN AC, SPITZ S. 1953. Malignant melanoma; a clinicopathological analysis of the criteria for diagnosis and prognosis. *Cancer*. Jan; 6(1):1-45.

<sup>48</sup>Ordóñez, Nelson G. "Value of melanocytic-associated immunohistochemical markers in the diagnosis of malignant melanoma: a review and update." *Human pathology* 45.2 (2014): 191-205.

<sup>49</sup>*Br J Ind Med*. 1991. Malignant melanomas of the nasal cavity after occupational exposure to formaldehyde. Holmstrom M, Lund VJ. Jan; 48(1):9-11.

<sup>50</sup>Axéll T, Hedin CA. *Scand J Dent Res*. 1982. Epidemiologic study of excessive oral melanin pigmentation with special reference to the influence of tobacco habits. Dec; 90(6):434-42.

<sup>51</sup>DeMatos, Pierre, Douglas S. Tyler, and Hilliard F. Seigler. "Malignant melanoma of the mucous membranes: a review of 119 cases." *Annals of surgical oncology* 5.8 (1998): 733-742.

<sup>52</sup>Thompson, Lester DR, Jacqueline A. Wieneke, and MarkkuMiettinen. "Sinonasal tract and nasopharyngeal melanomas: a clinicopathologic study of 115 cases with a proposed staging system." *The American journal of surgical pathology* 27.5 (2003): 594-611.

<sup>53</sup>Manolidis, Spiros, and Paul J. Donald. "Malignant mucosal melanoma of the head and neck." *Cancer* 80.8 (1997): 1373-1386.

<sup>54</sup>Thompson, Lester DR, Jacqueline A. Wieneke, and MarkkuMiettinen. "Sinonasal tract and nasopharyngeal melanomas: a clinicopathologic study of 115 cases with a proposed staging system." *The American journal of surgical pathology* 27.5 (2003): 594-611.

- 
- <sup>55</sup>Thompson LD, Wieneke JA, Miettinen M. Am J SurgPathol. 2003. Sinonasal tract and nasopharyngeal melanomas: a clinicopathologic study of 115 cases with a proposed staging system. May; 27(5):594-611.
- <sup>56</sup>Moreno, Mauricio A., et al. "Mucosal melanoma of the nose and paranasal sinuses, a contemporary experience from the MD Anderson Cancer Center."Cancer 116.9 (2010): 2215-2223.
- <sup>57</sup>Cheung, Michael C., et al. "Defining the role of surgery for primary gastrointestinal tract melanoma." Journal of gastrointestinal surgery 12.4 (2008): 731-738.
- <sup>58</sup>Reintgen, D. S., et al. "Radiologic, endoscopic, and surgical considerations of melanoma metastatic to the gastrointestinal tract." Surgery 95.6 (1984): 635-639.
- <sup>59</sup>Barrett AW, Raja AM. The immunohistochemical identification of human oral mucosal melanocytes. Arch Oral Biol 1997; 42: 77-81.
- <sup>60</sup>Aguas SC, Quarracino MC, Lence AN, Lanfranchi-Tizeira HE. Primary melanoma of the oral cavity: ten cases and review of 177 cases from literature. Med Oral Patol Oral Cir Bucal 2009; 14: E265-71.
- <sup>61</sup>Hicks, M. J., and C. M. Flaitz. "Oral mucosal melanoma: epidemiology and pathobiology." Oral oncology 36.2 (2000): 152-169.
- <sup>62</sup>Devi P, Bhovi T, Jayaram RR, Walia C, Singh S. Malignant melanoma of the oral cavity showing satellitism. J Oral Sci 2011; 53: 239-44.
- <sup>63</sup>Patel SG, Prasad ML, Escrig M, Singh B, Shaha AR, Kraus DH, Boyle JO, Huvos AG, Busam K, Shah JP. Primary mucosal malignant melanoma of the head and neck. Head Neck 2002; 24: 247-57.
- <sup>64</sup>Bisceglia M, Perri F, Tucci A, Tardio M, Panniello G, Vita G, Pasquinelli G. Primary malignant melanoma of the esophagus: a clinicopathologic study of a case with comprehensive literature review. AdvAnatPathol 2011; 18: 23552.
- <sup>65</sup>Elsayed, Al M., et al. "Malignant melanomas in the small intestine: a study of 103 patients." American Journal of Gastroenterology 91.5 (1996).
- <sup>66</sup>Amar A, Jougon J, Edouard A, Laban P, Marry JP, Hillion G. [Primary malignant melanoma of the small intestine]. GastroenterolClinBiol 1992; 16: 365-7.
- <sup>67</sup>Zhou HT, Zhou ZX, Zhang HZ, Bi JJ, Zhao P. Wide local excision could be considered as the initial treatment of primary anorectal malignant melanoma. Chin Med J (Engl) 2010; 123: 585-8.

- 
- <sup>68</sup>Gligorijevic J, Zivkovic V, Djordjevic B, Dimov I. Primary gallbladder melanoma in dysplastic nevus syndrome: report of case and literature review. *Turk J Gastroenterol* 2011; 22: 626-30.
- <sup>69</sup>Smith NE, Taube JM, Warczynski TM, Collier KD, Pawlik TM. Primary biliary tract melanoma: Report of a case and review of the literature. *Int J Surg Case Rep* 2012; 3: 441-4.
- <sup>70</sup>Chang, Alfred E., Lucy HyndsKarnell, and Herman R. Menck. "The National Cancer Data Base report on cutaneous and noncutaneous melanoma." *Cancer* 83.8 (1998): 1664-1678.
- <sup>71</sup>McLaughlin, Colleen C., et al. "Incidence of noncutaneous melanomas in the US." *Cancer* 103.5 (2005): 1000-1007.
- <sup>72</sup>Sugiyama, Valerie E., et al. "Vulvar melanoma: a multivariable analysis of 644 patients." *Obstetrics & Gynecology* 110.2, Part 1 (2007): 296-301.
- <sup>73</sup>Ragnarsson-Olding, Boel K., et al. "Malignant melanoma of the vulva in a nationwide, 25-year study of 219 Swedish females." *Cancer* 86.7 (1999): 1273-1284.
- <sup>74</sup>Verschraegen, C. F., et al. "Vulvar melanoma at the MD Anderson Cancer Center: 25 years later." *International Journal of Gynecological Cancer* 11.5 (2001): 359-364.
- <sup>75</sup>Balch, Charles M., et al. "Final version of 2009 AJCC melanoma staging and classification." *Journal of clinical oncology* 27.36 (2009): 6199-6206.
- <sup>76</sup>Markovic SN, Erickson LA, Rao RD, et al.; Melanoma Study Group of Mayo Clinic Cancer Center. Malignant melanoma in the 21st century, part 2: staging, prognosis, and treatment. *Mayo Clin Proc.* 2007;82(4):490-513.
- <sup>77</sup>American Cancer Society. Melanoma skin cancer. <http://www.cancer.org/cancer/skincancer-melanoma/detailedguide/melanoma-skin-cancer-survival-rates>. Accessed July 14, 2011.
- <sup>78</sup>American Academy of Dermatology. Melanoma: diagnosis, treatment, and outcome. <http://www.aad.org/skin-conditions/dermatology-a-to-z/melanoma/diagnosis/treatment/melanoma-diagnosis-treatment-and-outcome>. Accessed July 14, 2011.
- <sup>79</sup>McKenna JK, Florell SR, Goldman GD, Bowen GM. Lentigo maligna/lentigo maligna melanoma: current state of diagnosis and treatment. *Dermatol Surg.* 2006;32(4):493-504.
- <sup>80</sup>Garbe, Claus, et al. "Evidence and interdisciplinary consensus-based German guidelines: surgical treatment and radiotherapy of melanoma." *Melanoma research* 18.1 (2008): 61-67.
- <sup>81</sup>Garbe, Claus, et al. "Treatment of melanoma." *DtschArzteblInt* 105.49 (2008): 845-51.

- 
- <sup>82</sup>Hauschild, A., et al. "[Safety margins in the excision of primary malignant melanoma. Proposals based on controlled clinical trials]." *Der Hautarzt; Zeitschrift für Dermatologie, Venerologie, und verwandte Gebiete* 52.11 (2001): 1003-1010.
- <sup>83</sup>Garbe C, Hauschild A, Volkenandt M et al.: Evidence-based and interdisciplinary consensus-based German guidelines: systemic medical treatment of melanoma in the adjuvant and palliative setting. *Melanoma Res* 2008; 18: 152–60.
- <sup>84</sup>Garbe, Claus, et al. "Kurzleitlinie–Malignes Melanom der Haut." *JDDG: Journal der Deutschen Dermatologischen Gesellschaft* 6.s1 (2008).
- <sup>85</sup> Wheatley K, Ives N, Eggermont AM et al.: Interferon-alpha as adjuvant therapy for melanoma: an individual patient data metaanalysis of randomised trials. *J Clin Oncol* 2007; 25: 8526.
- <sup>86</sup>Bos, Johannes L. "Ras oncogenes in human cancer: a review." *Cancer research* 49.17 (1989): 4682-4689.
- <sup>87</sup>Barbacid, M., 1987. Ras genes. *Annu. Rev. Biochem.* 56, 779–827.
- <sup>88</sup> Anton, P., Suzanne, E., Ulrik, R., Johan, H., 2007. Human cutaneous melanoma; a review of NRAS and BRAF mutation frequencies in relation to histogenetic subclass and body site. *Molecular oncology.* 1 (2008) 395–405.
- <sup>89</sup>Knobbe, Christiane B., Julia Reifenberger, and Guido Reifenberger. "Mutation analysis of the Ras pathway genes NRAS, HRAS, KRAS and BRAF in glioblastomas." *Actaneuropathologica* 108.6 (2004): 467-470.
- <sup>90</sup>Bos, J.L., 1989. Ras oncogenes in human cancer: a review. *Cancer Res.* 49, 4682–4689.
- <sup>91</sup>Omholt, K., Platz, A., Kanter, L., Ringborg, U., Hansson, J., 2003. NRAS and BRAF mutations arise early during melanoma pathogenesis and are preserved throughout tumor progression. *Clin. Cancer Res.* 9, 6483–6488.
- <sup>92</sup>Peyssonnaud, Carole, and Alain Eychène. "The Raf/MEK/ERK pathway: new concepts of activation." *Biology of the Cell* 93.1-2 (2001): 53-62.
- <sup>93</sup>Downward, Julian. "Targeting RAS signalling pathways in cancer therapy." *Nature Reviews Cancer* 3.1 (2003): 11-22.
- <sup>94</sup>Ascierto, Paolo A., et al. "The role of BRAF V600 mutation in melanoma." *J Transl Med* 10.85 (2012): 10-1186.
- <sup>95</sup>Haluska, Frank G., et al. "Genetic alterations in signaling pathways in melanoma." *Clinical Cancer Research* 12.7 (2006): 2301s-2307s.

- 
- <sup>96</sup> Kumar, R., Angelini, S., Hemminki, K., 2003a. Activating BRAF and N-Ras mutations in sporadic primary melanomas: an inverse association with allelic loss on chromosome 9. *Oncogene* 22, 9217–9224.
- <sup>97</sup> Pollock PM, Harper UL, Hansen KS, et al. High frequency of BRAF mutations in nevi. *Nat Genet* 2003; 33:19–20.
- <sup>98</sup> Zhang, B.H., Guan, K.L., 2000. Activation of B-Raf kinase requires phosphorylation of the conserved residues Thr598 and Ser601. *Embo J* 19, 5429–5439.
- <sup>99</sup> Davies, H., Bignell, G.R., Cox, C., Stephens, P., Edkins, S., Clegg, S., Teague, J., Woffendin, H., Garnett, M.J., Bottomley, W., Davis, N., et al., 2002. Mutations of the BRAF gene in human cancer. *Nature* 417, 949–954.
- <sup>100</sup> Long GV, Menzies AM, Nagrial AM, Haydu LE, Hamilton AL, Mann GJ, Hughes TM, Thompson JF, Scolyer RA, Kefford RF: Prognostic and clinicopathologic associations of oncogenic BRAF in metastatic melanoma. *J Clin Oncol* 2011, 29:1239–1246.
- <sup>101</sup> Curtin JA, Busam K, Pinkel D, Bastian BC. *J Clin Oncol*. 2006. Somatic activation of KIT in distinct subtypes of melanoma. Sep 10; 24(26):4340-6.
- <sup>102</sup> Beadling C, Jacobson-Dunlop E, Hodi FS, Le C, Warrick A, Patterson J, et al. KIT gene mutations and copy number in melanoma subtypes. *Clin Cancer Res* 2008;14:6821–8.
- <sup>103</sup> Handolias D, Hamilton AL, Salemi R, Tan A, Moodie K, Kerr L, et al. Clinical responses observed with imatinib or sorafenib in melanoma patients expressing mutations in KIT. *Br J Cancer* 2010;102:1219–23.
- <sup>104</sup> Omholt, Katarina, et al. "KIT pathway alterations in mucosal melanomas of the vulva and other sites." *Clinical Cancer Research* 17.12 (2011): 3933-3942.
- <sup>105</sup> Bologna SB, Nico MM, Hsieh R, Coutinho-Camillo CM, Buim ME, Fernandes JD, Sanguenza M, Soares FA, Lourenço SV. *Am J Dermatopathol*. 2013. Adhesion molecules in primary oral mucosal melanoma: study of claudins, integrins and immunoglobulins in a series of 35 cases. Jul; 35(5):541-54.
- <sup>106</sup> Rivera RS, Nagatsuka H, Gunduz M, Cengiz B, Gunduz E, Siar CH, Tsujigiwa H, Tamamura R, Han KN, Nagai N. *Virchows Arch*. 2008. C-kit protein expression correlated with activating mutations in KIT gene in oral mucosal melanoma. Jan; 452(1):27-32.
- <sup>107</sup> Davies, Helen, et al. "Mutations of the BRAF gene in human cancer." *Nature* 417.6892 (2002): 949-954.



- 
- <sup>108</sup>Woodman, Scott E., et al. "Activity of dasatinib against L576P KIT mutant melanoma: molecular, cellular, and clinical correlates." *Molecular cancer therapeutics* 8.8 (2009): 2079-2085.
- <sup>109</sup>Beadling, Carol, et al. "KIT gene mutations and copy number in melanoma subtypes." *Clinical Cancer Research* 14.21 (2008): 6821-6828.
- <sup>110</sup>Van Raamsdonk, Catherine D., et al. "Mutations in GNA11 in uveal melanoma." *New England Journal of Medicine* 363.23 (2010): 2191-2199.
- <sup>111</sup>Samarskij, Aleksandr A., and Evgenii S. Nikolaev. *Numerical Methods for Grid Equations: Volume II Iterative Methods*. Birkhäuser, 2012.
- <sup>112</sup>Flaherty, Keith T., et al. "Combined BRAF and MEK inhibition in melanoma with BRAF V600 mutations." *New England Journal of Medicine* 367.18 (2012): 1694-1703.
- <sup>113</sup>Clark WH Jr, Elder DE, Guerry D 4th, Braitman LE, Trock BJ, Schultz D, Synnestvedt M, Halpern ACJ *Natl Cancer Inst.* 1989 Dec 20; 81(24):1893-904.
- <sup>114</sup>Maurer, G., Bartek Tarkowski, and Manuela Baccarini. "Raf kinases in cancer—roles and therapeutic opportunities." *Oncogene* 30.32 (2011): 3477-3488.
- <sup>115</sup>Curtin, John A., et al. "Distinct sets of genetic alterations in melanoma." *New England Journal of Medicine* 353.20 (2005): 2135-2147.
- <sup>116</sup>Johnson, Douglas B., and Igor Puzanov. "Treatment of NRAS-mutant melanoma." *Current treatment options in oncology* 16.4 (2015): 1-12.
- <sup>117</sup>Beadling, Carol, et al. "KIT gene mutations and copy number in melanoma subtypes." *Clinical Cancer Research* 14.21 (2008): 6821-6828.
- <sup>118</sup>Torres-Cabala, Carlos A., et al. "Correlation between KIT expression and KIT mutation in melanoma: a study of 173 cases with emphasis on the acral-lentiginous/mucosal type." *Modern Pathology* 22.11 (2009): 1446-1456.
- <sup>119</sup> Carlos A. Torres-Cabala, Jonathan L. Curry. *Genetics of Melanoma*. New York. 2016. Pp 154-160
- <sup>120</sup>Corless, Christopher L., and Michael C. Heinrich. "Molecular pathobiology of gastrointestinal stromal sarcomas." *Annu. Rev. pathmechdis. Mech. Dis.* 3 (2008): 557-586.
- <sup>121</sup>Lennartsson, Johan, et al. "Phosphorylation of Shc by Src family kinases is necessary for stem cell factor receptor/c-kit mediated activation of the Ras/MAP kinase pathway and c-fos induction." *Oncogene* 18.40 (1999): 5546-5553.

- 
- <sup>122</sup>Ishihara K, Saida T, Otsuka F, et al.(2008) Statistical profiles of malignant melanoma and other skin cancers in Japan: 2007 update. *Int J Clin Oncol*13:33–41.
- <sup>123</sup>Balch CM, Buzaid AC, Soong SJ, et al. (2001) Final version of the American Joint Committee on Cancer staging system for cutaneous melanoma. *J Clin Oncol* 19:3635–3648.
- <sup>124</sup>Guo, Jun, et al. "Phase II, open-label, single-arm trial of imatinib mesylate in patients with metastatic melanoma harboring c-Kit mutation or amplification." *Journal of Clinical Oncology* 29.21 (2011): 2904-2909.
- <sup>125</sup>Oumeish., O.Y. 1997. Epidemiology of primary cutaneous malignant melanoma in Jordan. *Int J Dermatol.* Feb;36(2):113-5.
- <sup>126</sup> Awad, Al-Tarawneh., Nabih Al-Kaisi. 2008. Cutaneous malignant melanoma: a clinopathological study of 24 cases. *JRMS* Aug 15(2): 73-78.
- <sup>127</sup>Massad, C., et al. "BRAF mutation status in primary and metastatic melanomas in two regions with differing potential ultraviolet radiation exposure." *Clinical and experimental dermatology* 39.8 (2014): 932-943.
- <sup>128</sup>Shelton, Trent, et al. "Tracheal metastasis from melanoma detected with 18F-FDG PET/CT." *Clinical nuclear medicine* 38.10 (2013): 815-817.
- <sup>129</sup>F. Stephen Hodi. 2015. ,Imatinib in patients with mucosal or acral lentiginous melanoma. Dana-Farber Cancer Institute. August 23.
- <sup>130</sup>Hussein, Mahmoud R. "Skin cancer in Egypt: a word in your ear." *Cancer biology & therapy* 4.5 (2005): 593-595.
- <sup>131</sup>Hussein, Mahmoud R. "Extracutaneous malignant melanomas." *Cancer investigation* 26.5 (2008): 516-534.
- <sup>132</sup>Hussein, Mahmoud R. "Ultraviolet radiation and skin cancer: molecular mechanisms." *Journal of cutaneous pathology* 32.3 (2005): 191-205.
- <sup>133</sup>Samaka, Rehab M., and Mohammed A. Gaber. "Ephrin A4 Immunohistochemical Expression in Cutaneous Melanoma." (2010).
- <sup>134</sup>Pedergnana, Vincent, et al. "Refined association of melanoma differentiation-associated gene 5 variants with spontaneous hepatitis C virus clearance in Egypt." *Hepatology* (2015).
- <sup>135</sup>Mostafa, Mohamed G., et al. "Gastric metastases from invasive primary mucosal epithelioid malignant melanoma of the hard palate: report of the first case in the English literature." *Expert review of gastroenterology & hepatology*8.1 (2014): 15-19.

---

<sup>136</sup> Mufti ST. Pattern of cutaneous melanoma at King Abdulaziz University Hospital, Jeddah, Saudi Arabia. *Pak J Med Sci* 2012;28(1):154-157.

<sup>137</sup>Sharquie, Khalifa E., Adil A. Noaim, and Wesal K. Al-Janabi. "The Status of Malignant Melanoma in Iraqi Patients." *American Journal of Dermatology and Venereology* 3.3 (2014): 63-67.

<sup>138</sup>Pour, Maryam AH, et al. "Malignant mucosal melanoma of the head and neck diagnosed in an Iranian population over an 11-year period." *American Journal of Applied Sciences* 6.8 (2009): 1467.

<sup>139</sup>Yakobson, Emanuel, et al. "Two p16 (CDKN2A) germline mutations in 30 Israeli melanoma families." *European Journal of Human Genetics* 8.8 (2000): 590-596.

<sup>140</sup>Hazzan, D., et al. "Primary rectal malignant melanoma: report of two cases." *Techniques in coloproctology* 5.1 (2001): 51-54.

<sup>141</sup>Lotem, Michal, et al. "Mucosal melanoma of the female genital tract is a multifocal disorder." *Gynecologic oncology* 88.1 (2003): 45-50.